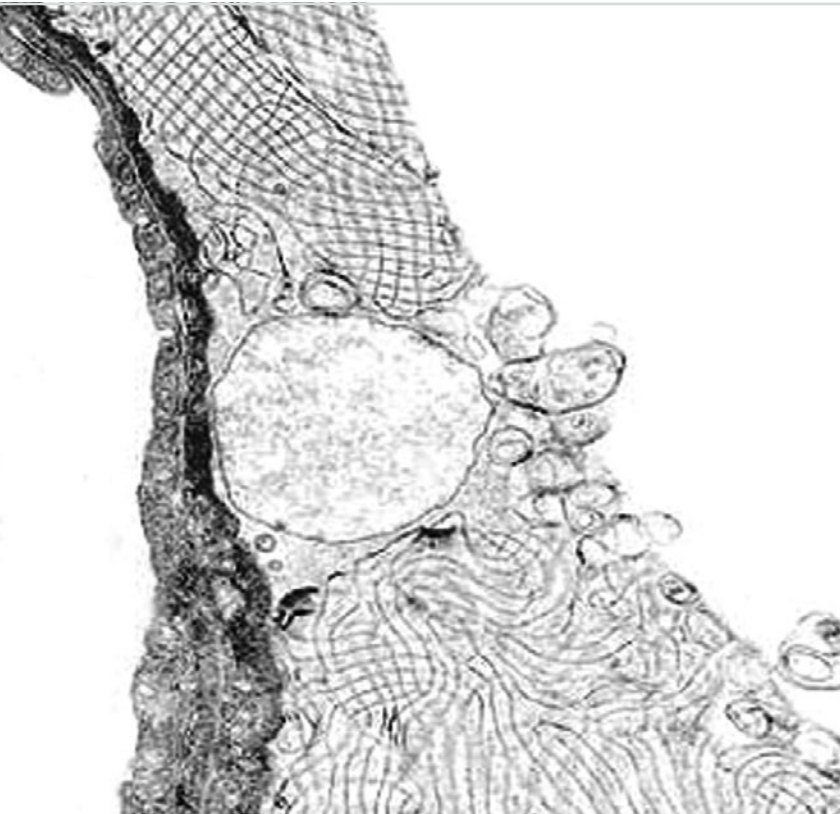


SWISS SOCIETY OF NEONATOLOGY

Winner of the
Case of the Year
Award 2011

Favorable long-term outcome
of a patient with ABCA3
gene mutations and severe
neonatal lung disease

FEBRUARY 2011



Morgillo D, Fontana M, Eng P, Berger TM, Neonatal and Pediatric Intensive Care Unit (MD, FM, BTM), Pediatric Pulmonology (EP), Children's Hospital of Lucerne, Switzerland

Pulmonary surfactant is a phospholipid-protein complex synthesized in alveolar type II cells. It lowers surface tension and prevents atelectasis at end-expiration. Mutations in genes of the surfactant synthetic pathway (surfactant protein-B, surfactant protein-C and ATP-binding cassette member A3) disrupt surfactant function and cause respiratory disease in newborns and older children (1).

ABCA3 is one of a large family of ATP-binding cassette (ABC) transporters that has been localized to the limiting membrane of lamellar bodies in alveolar type II cells. Recessive loss-of-function mutations in ABCA3 genes present as lethal surfactant deficiency in the newborn (2), whereas other recessive mutations in ABCA3 can result in interstitial lung disease (3).

Outcome of patients with ABCA3 gene mutations is highly variable, ranging from fatal neonatal respiratory failure to long-term survival with mild chronic lung disease (4). Currently, it is not possible to make firm prognostic predictions based on the ABCA3 genotype. However, patients with ABCA3 gene mutations who present with severe respiratory failure in the immediate postnatal period are considered to have a poor prognosis.

CASE REPORT

This female infant was delivered at 38 6/7 weeks by elective repeat caesarean section at another institution following an otherwise unremarkable pregnancy. The baby girl adapted without difficulties with Apgar scores of 8, 9 and 9 at 1, 5 and 10 minutes, respectively. The arterial umbilical cord pH was 7.29. Her birth weight was 3630 g. She rapidly developed respiratory distress and was transferred to our neonatal intensive care unit on nasal CPAP. Given her gestational age and mode of delivery, transient tachypnea of the newborn was considered to be the most likely diagnosis, however, her CXR revealed the typical appearance of hyaline membrane disease (Fig. 1).

On day of life (DOL) 2, she developed a right-sided pneumothorax and pneumomediastinum (Fig. 2). She was intubated and surfactant was administered (Curosurf®, poractant alfa). The pneumothorax was successfully evacuated through a 22G intravenous cannula (Fig. 3) but reoccurred a few hours later (Fig. 4) requiring placement of a chest tube (Fig. 5). Two days later, she developed a pneumothorax on the left side (Fig. 6) that was drained with a chest tube (Fig. 7). At this time she was supported with high frequency oscillatory ventilation (HFOV) and inhaled nitric oxide (iNO) for suprasystemic pulmonary hypertension. On DOL 6, the air leaks had almost completely resolved (Fig. 8) but she remained ventilator-dependent. On DOL 10, she was started on dexamethasone and she was extubated to nasal prong CPAP 6 days later (Fig. 9). The steroids were

weaned and discontinued on DOL 26, but had to be restarted due to worsening lung function only 4 days later.

Given the unusual course of respiratory distress in this term infant, genetic analyses were performed in Munich (Prof. M. Griese: SP-B, SP-C genes) and Regensburg (Prof. C. Aslanidis: ABCA3 gene). No mutations were found on SP-B and SP-C genes. Analysis of the ABCA3 gene revealed two heterozygous mutations: c.875A>T (Glu292Val) and c.2293G>T (stop codon Glu 765stop). Analyses of blood samples from the parents confirmed that the father carried the c.875A>T (Glu-292Val) mutation and the mother the c.2293G>T (stop codon Glu 765stop) mutations.

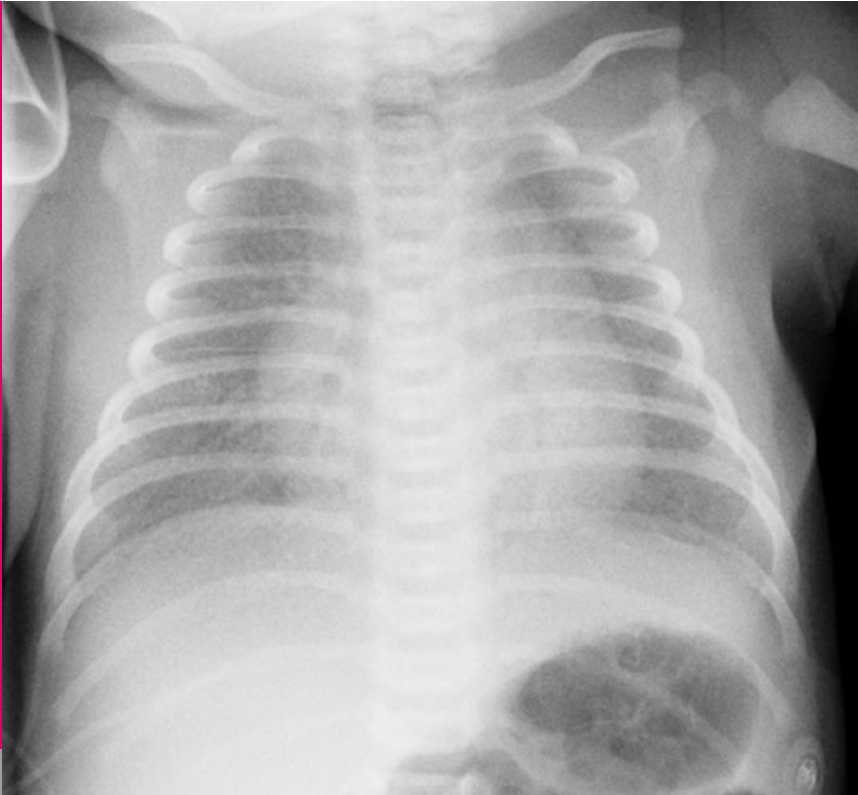


Fig. 1

CXR on DOL 1: fine reticulogranular pattern consistent with hyaline membrane disease.

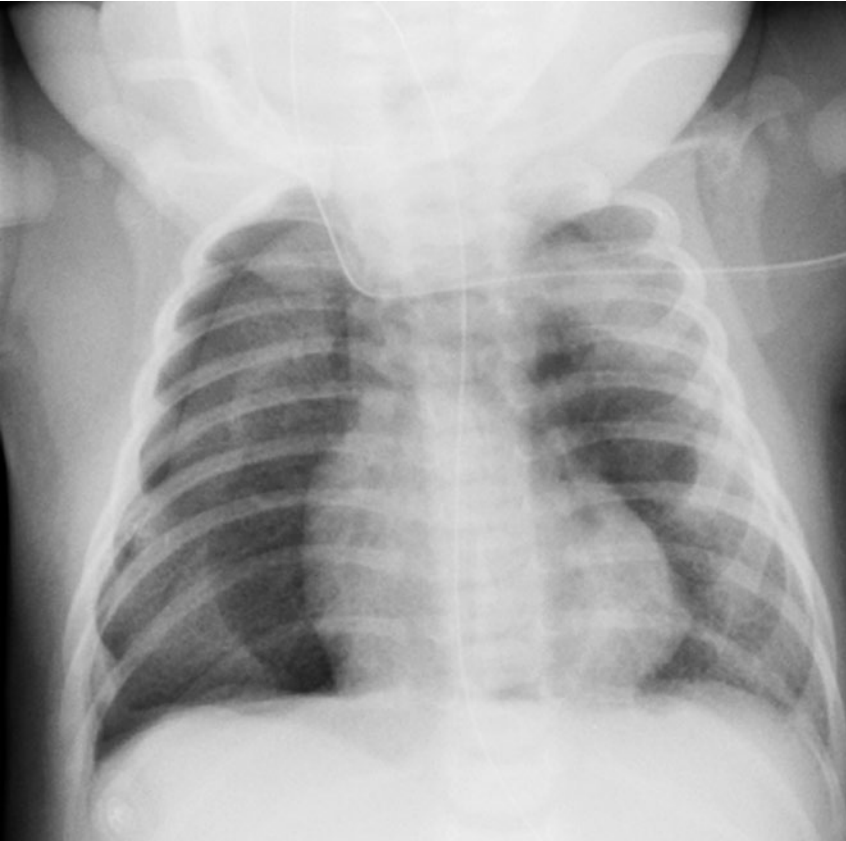


Fig. 2

CXR on DOL 2: right-sided pneumothorax and pneumomediastinum.

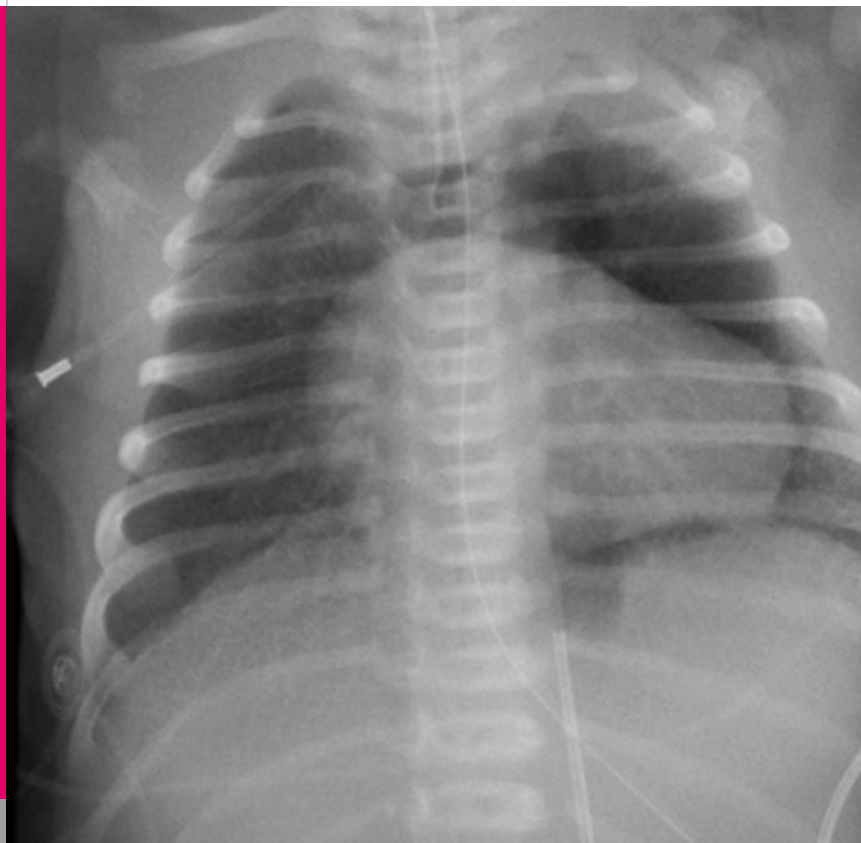

Fig. 3

CXR on DOL 2: reexpansion of the right lung following thoracocentesis with a 22G intravenous cannula.

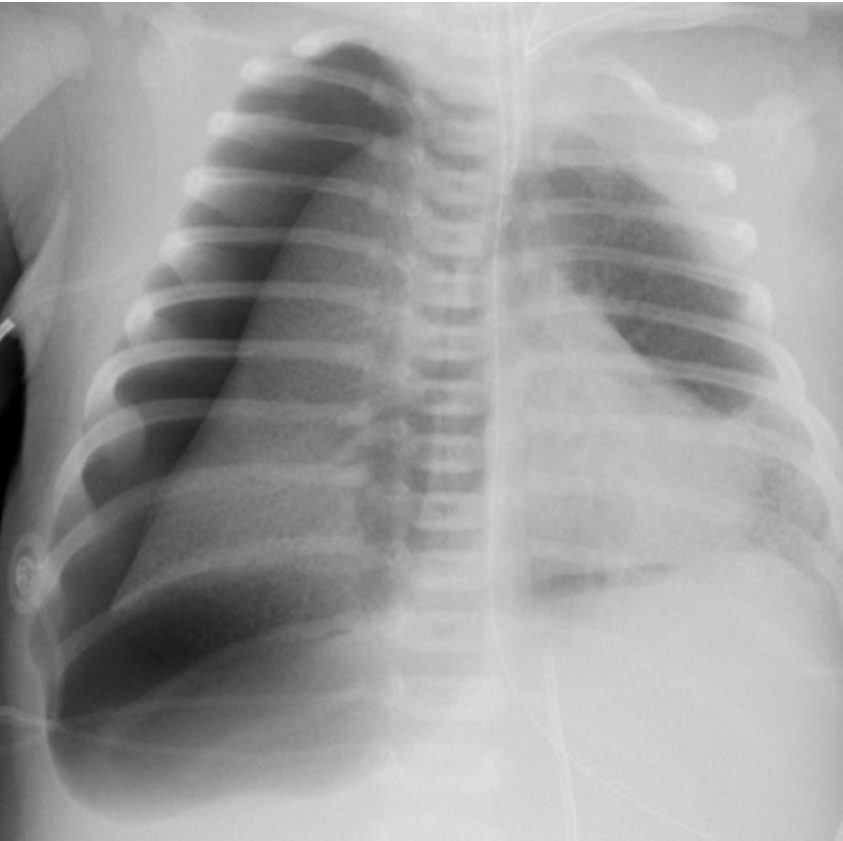

Fig. 4

CXR on DOL 2: increase of right-sided pneumothorax despite continuous suction through a 22G intravenous cannula.

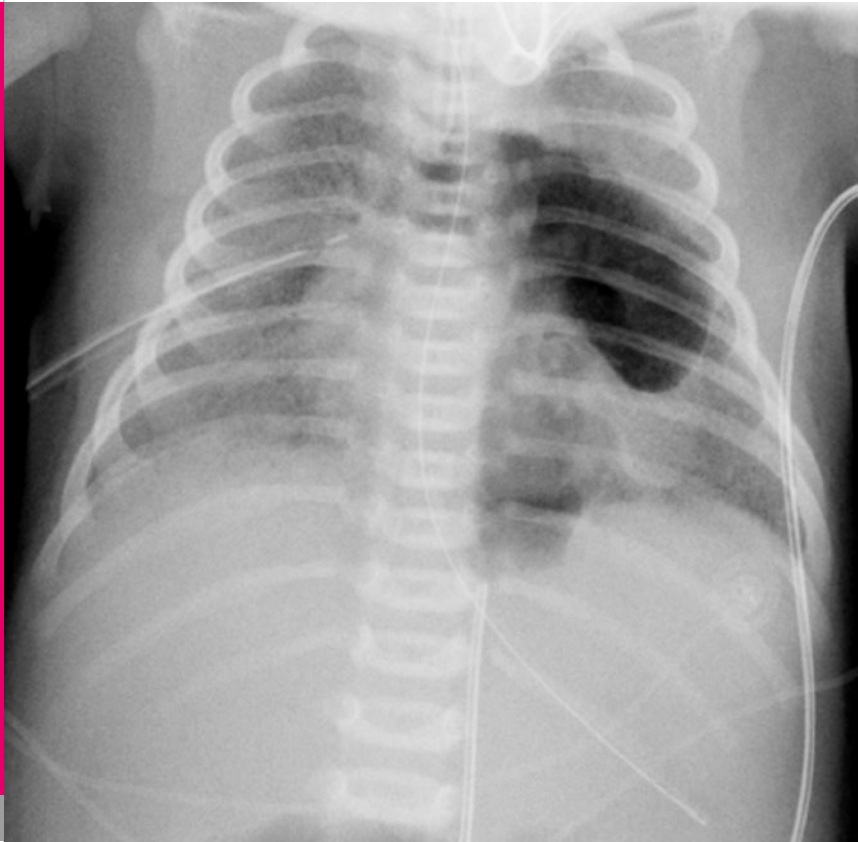
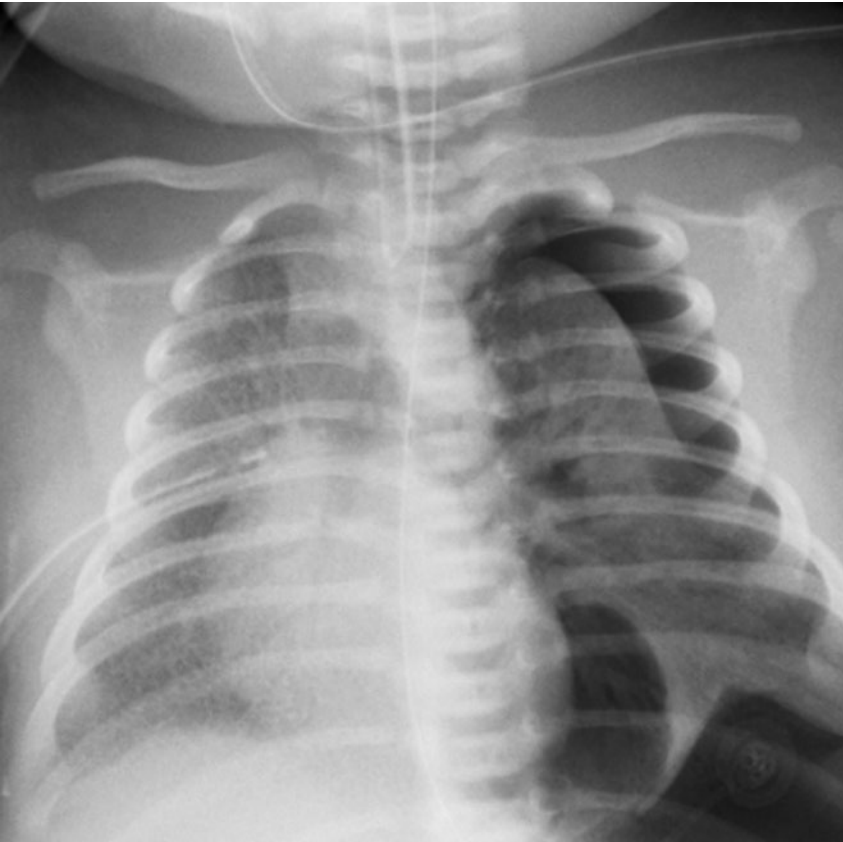
Fig. 5

CXR on DOL 2: appearance following placement of a pleural drain.



CXR on DOL 4: left-sided pneumothorax.

Fig. 6

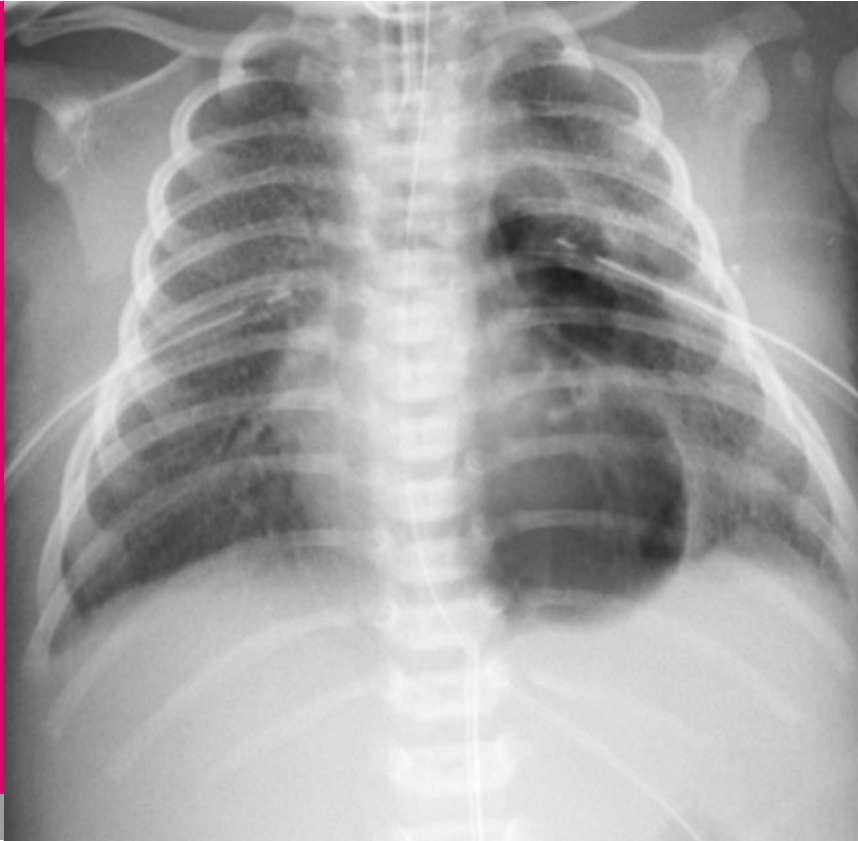

Fig. 7

CXR on DOL 4: appearance following chest tube insertion into the left pleural space.

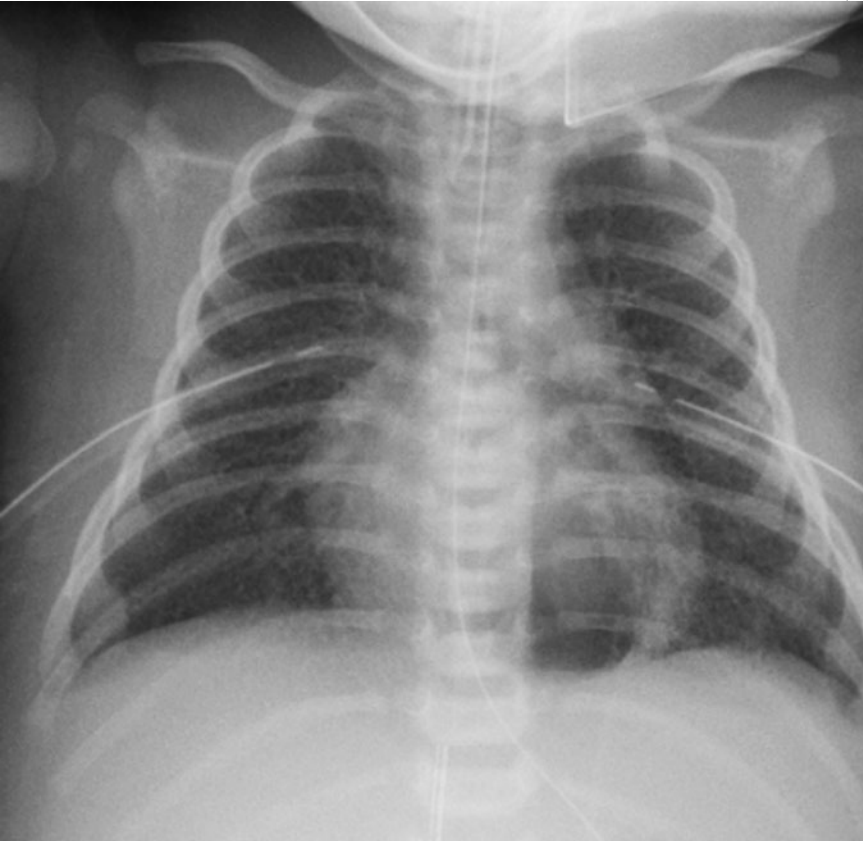


Fig. 8

CXR on DOL 6: resolution of bilateral pneumothoraces, residual pneumomediastinum.

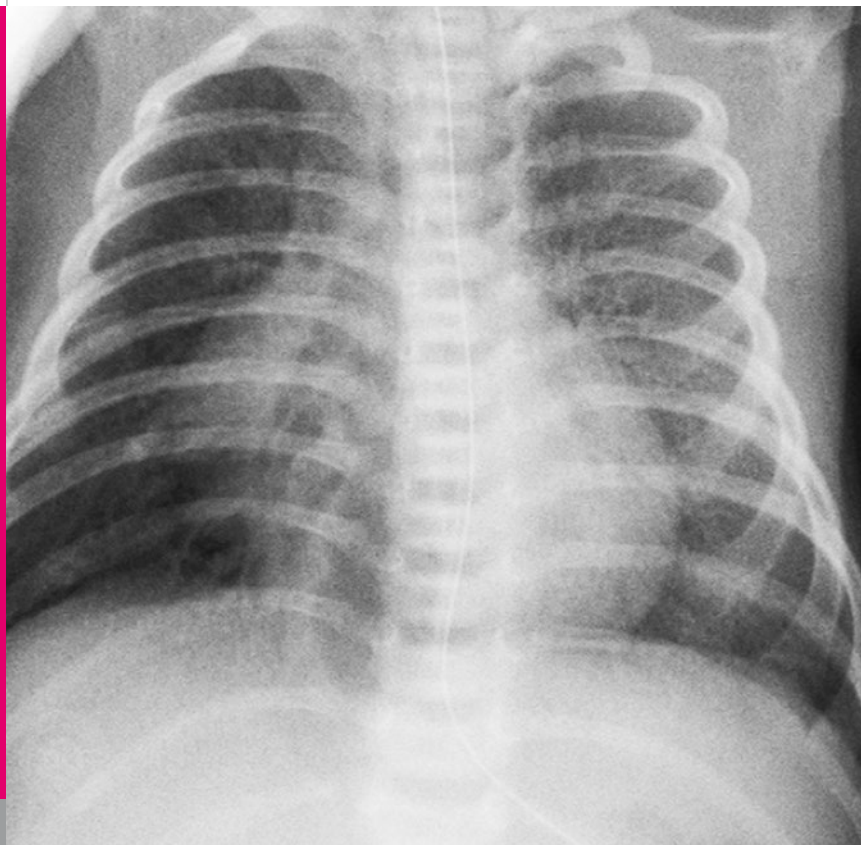


Fig. 9

CXR on DOL 17: chest tubes have been removed and the infant has been extubated.

On DOL 45, she had to be reintubated. Two days later, when her CXR again worsened (Fig. 10), she was started on hydroxychloroquine (10 mg/kg/day divided in two doses). Mechanical ventilation was continued until DOL 73. Finally, at the age of 3.5 months, she was discharged on supplementary oxygen (FiO₂ 1.0, minimal flow 0.3 l/Min) and hydroxychloroquine (Fig. 11).

Over the following two months, she was rehospitalized twice for severe respiratory failure secondary to presumed respiratory tract infections and again required HFOV (Fig. 12). Over the following months, her condition stabilized and, at the age of 10 months while still on hydroxychloroquine, she came off supplementary oxygen (Fig. 13). Viral infections at the age of 16 and again 20 months led to hospital admissions but no mechanical ventilatory support was necessary. The patient is now three years old, remains on hydroxychloroquine and off supplementary oxygen (Fig. 14, 15).

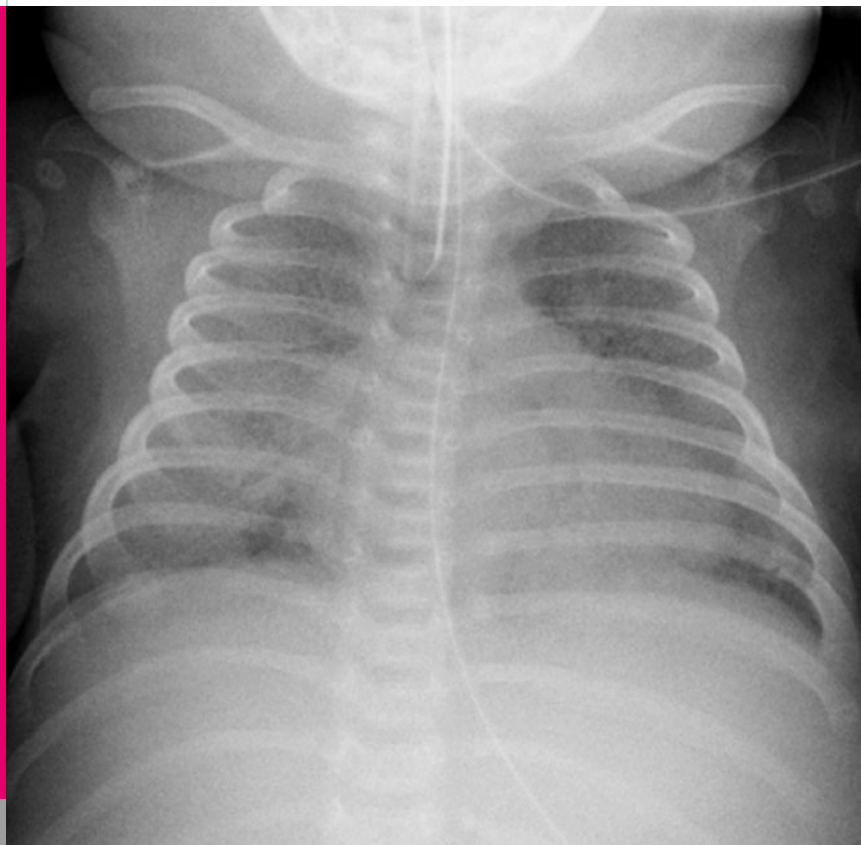


Fig. 10

*CXR on DOL 47: two days following reintubation
bilateral opacities persist.*

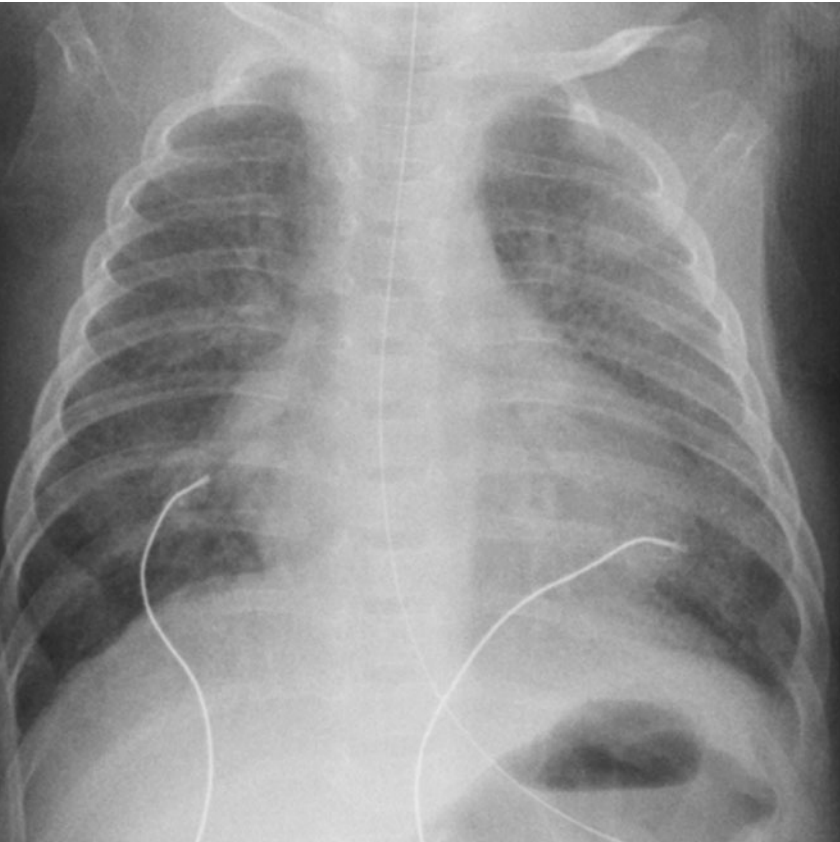


Fig. 11

CXR at the age of 3.5 months: the infant is discharged home on hydroxychloroquine and supplemental oxygen by nasal cannula.

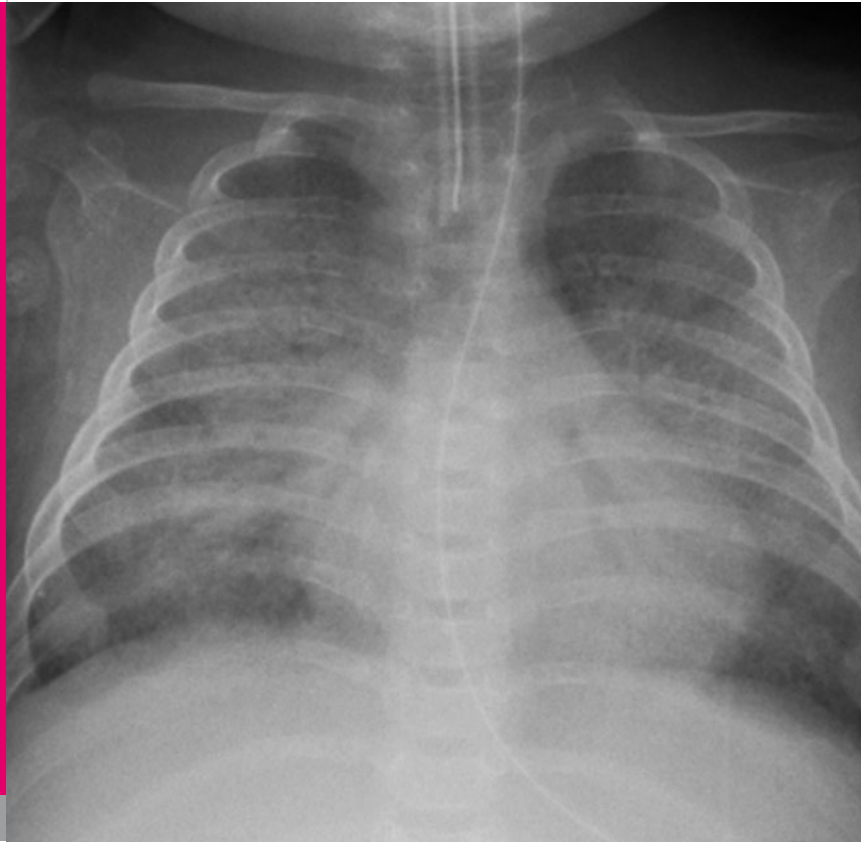


Fig. 12

CXR at the age of 5 months: the child has been reintubated for severe respiratory failure and is supported with high frequency oscillatory ventilation.

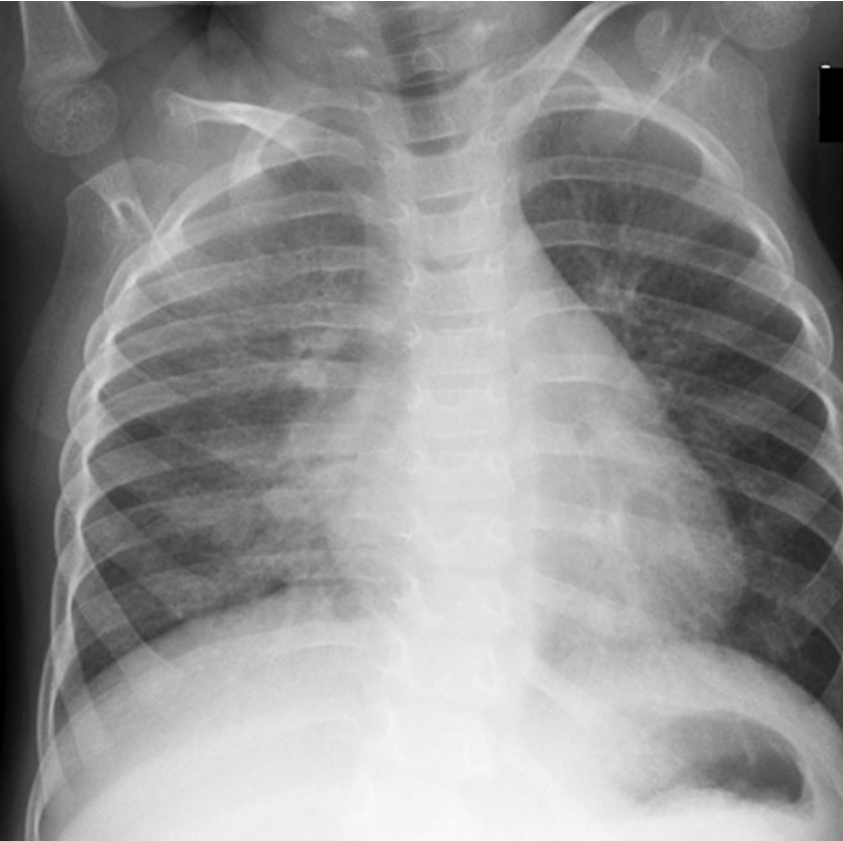


Fig. 13

CXR at the age of 10 months: the child is still on hydroxychloroquine but off supplementary oxygen for the first time of her life.

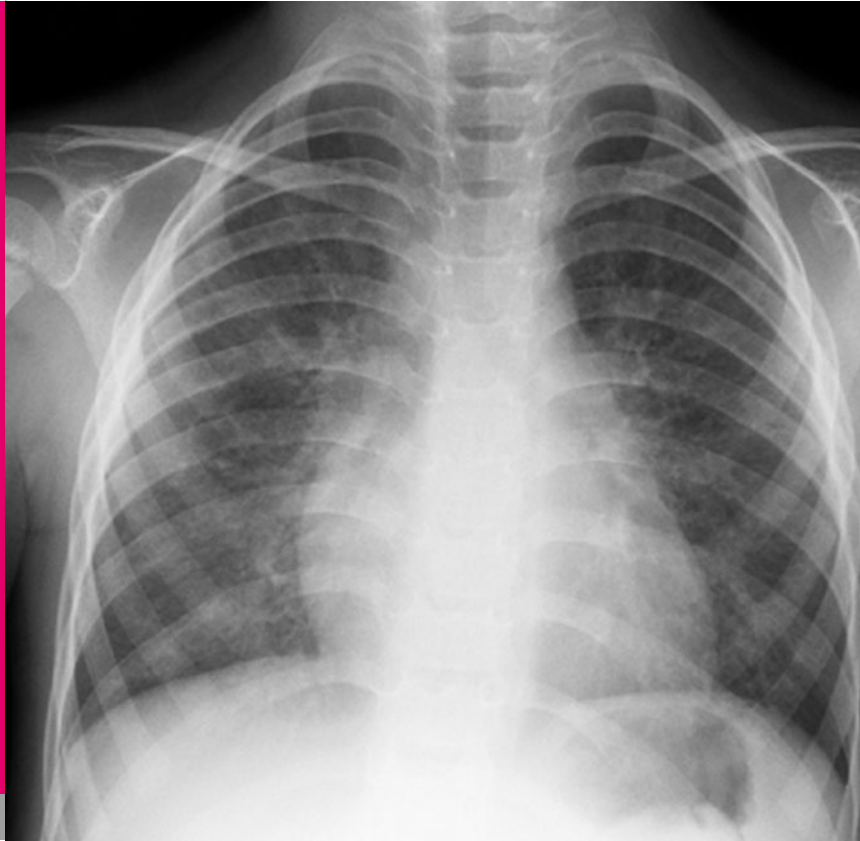

Fig. 14

CXR at the age of 3 years: mild bilateral interstitial lung disease (on hydroxychloroquine, but off supplemental oxygen with normal SaO₂ concentrations).



Fig. 15

Patient at the age of 3 years: off supplemental oxygen, but still on hydroxychloroquine (7 mg/kg/day divided in 2 doses).

DISCUSSION

ABCA3 gene mutations - as well as SP-B and SP-B deficiencies - should be included in the differential diagnosis of a full-term infant who presents with respiratory failure and fails to recover within the first two weeks of life. Based on published case series, patients with ABCA3 gene mutations who present with severe respiratory failure in the neonatal period, appear to have a poor prognosis (4). On the other hand, in one case series, the age at symptom onset for nearly half of the patients with ABCA3 mutations was beyond the neonatal period and extended to early childhood when the disease presented as chronic interstitial lung disease (ILD) (3, 4).

Our patient was found to be compound heterozygous for two ABCA3 mutations, one of which has previously described and is known to be disease-associated (Glu292Val), and the other of which has not yet been described but is almost certainly a disease-causing mutation as it introduces a premature termination codon likely to be associated with markedly reduced mRNA levels due to nonsense-mediated degradation. Such a "null" allele precludes any functional ABCA3 from being made (Larry Noguee, personal communication). Given the early onset and severity of illness, coupled with the described ABCA3 gene mutations, we feared that our patient would not be a long-term survivor. Palliative care was considered to be an option when our patient was still on mechanical respiratory support after more than two months of life and again when she

had to be reintubated at the age of 5 and 6 months. Fortunately, our predictions proved to be wrong. Hydroxychloroquine is one of a number of drugs that have been used for many years in the treatment of malaria. The use of hydroxychloroquine in the therapy of ILD has been reported and has been used most frequently as a corticosteroid sparing agent with anecdotal success. While hydroxychloroquine has for some time been known to increase lysosomal pH in antigen presenting cells, its mechanism of action in inflammatory conditions has recently been elucidated and involves blocking the activation of toll-like receptors on plasmacytoid dendritic cells. Toll-like receptor 9 (TLR 9), which recognizes DNA-containing immune complexes, leads to the production of interferon and causes the dendritic cells to mature and present antigen to T cells. Hydroxychloroquine, by decreasing TLR signalling, reduces the activation of dendritic cells thus mitigating the inflammatory process (5, 6). In 2005, Rosen et al. reported on an infant with SP-C deficiency that was treated successfully with hydroxychloroquine. They suggested that, in addition to its anti-inflammatory properties, hydroxychloroquine inhibits intracellular processing of the precursor of SP-C, which may be the mechanism of action in that disorder (7).

Recently, the results of a phase II trial with PTC124 in patients with cystic fibrosis caused by nonsense mutations due to premature termination codons have been

published (8). PCT124 is an orally bioavailable non-aminoglycoside compound that can induce ribosomes to read through premature stop codons but not normal stop codons. It therefore has the potential to overcome nonsense mutations without affecting normal protein synthesis (8). During treatment, CFTR-mediated total chloride transport increased significantly. No drug-related serious adverse events were recorded. Evaluation of this novel therapy is still at an early stage, but if proven effective and safe, PCT124 would potentially be a treatment option for our patient.

In summary, we have presented a patient with two ABCA3 gene mutations who presented with severe neonatal lung disease and two additional episodes of severe respiratory failure in the first six months of life which required invasive respiratory support with HFOV. Fortunately, she appears to have responded to hydroxychloroquine therapy and, at the age of three years, is off supplemental oxygen with normal SaO₂ values.

See also: **COTM 01/2008**: Fatal surfactant deficiency in two siblings caused by a novel ABCA3 gene mutation.

We would like to thank the following colleagues for their support in the evaluation and management of our patient (in alphabetical order): Leland L. Fan (Texas Children's Hospital, Houston, TX), Matthias Griesse (Haunersches Kinderspital Munich, Germany), Jürg Hammer (University Children's Hospital of Basel, Switzerland), Larry M. Nogee (Johns Hopkins University School of Medicine, Baltimore, MD), and Lisa R. Young (Cincinnati Children's Hospital Medical Center, Cincinnati, OH).

We also are grateful to the parents for allowing us to use a recent photograph of the patient.

REFERENCES

1. Hamvas A, Cole FS, Nogee LM. Genetic disorders of surfactant proteins. *Neonatology* 2007;91:311-317
2. Shulenin S, Nogee LM, Annilo T, Wert S, Whitsett JA, Dean M. ABCA3 gene mutations in newborns with fatal surfactant deficiency. *N Engl J Med* 2004;350:1296-1303
3. Bullard JE, Wert SE, Lawrence M, Nogee LM. ABCA3 Deficiency: Neonatal respiratory failure and interstitial lung disease.
4. Doan ML, Guillerman RP, Dishop MK, Nogee LM, Langston C, Mallory GB, Sockrider MM, Fan LL. Clinical, radiological and pathological features of ABCA3 mutations in children. *Thorax* 2008;63:366-373
5. Ben-Zvi I, Kivity S, Langevitz P, Shoenfeld Y. Hydroxychloroquine: From malaria to autoimmunity. *Clin Rev Allergy Immunol* 2011 Jan 8. [Epub ahead of print]
6. Hemmi H, Akira S. TLR signalling and the function of dendritic cells. *Chem Immunol Allergy* 2005;86:120-135
7. Rosen DM, Waltz AD. Hydroxychloroquine and surfactant prote in C deficiency. *N Engl J Med* 2005;352:207-208
8. Kerem E, Hirawat S, Armoni S, et al. Effectiveness of PCT214 treatment of cystic fibrosis caused by nonsense mutations: a prospective phase II trial. *Lancet* 2008;372:719-727

