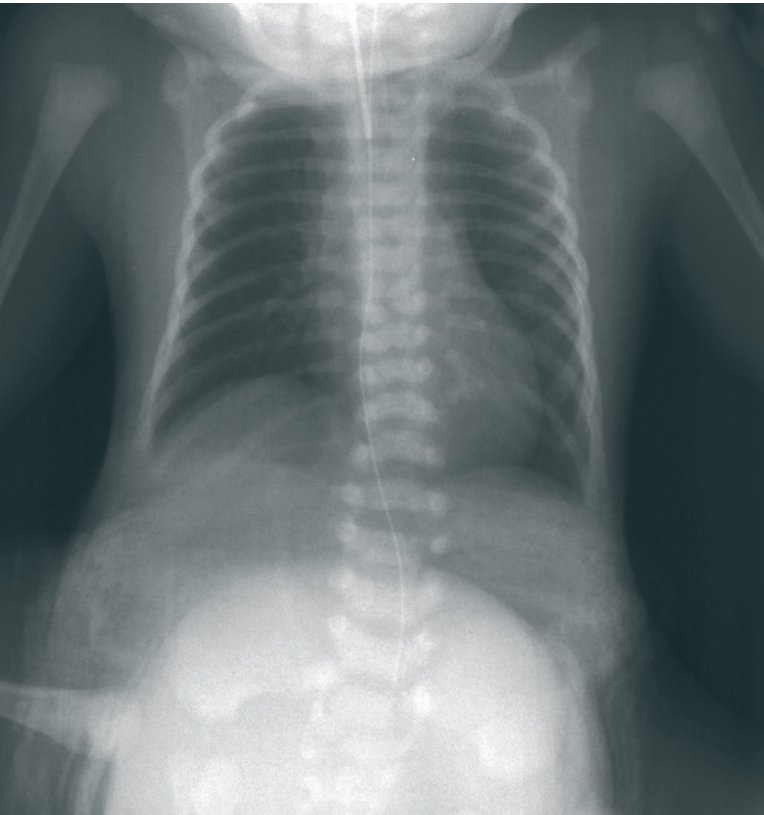


SWISS SOCIETY OF NEONATOLOGY

OEIS Complex:
developmental insights into a
severe congenital abnormality
of body wall development



MARCH 2008

This infant was a premature boy born at 33 weeks and 6 days gestation to a 28-year-old American G1/P1 who had received regular prenatal care. The parents were non-consanguineous. There was no family history of any major malformation, birth defects or mental retardation. Pregnancy was uneventful and there was no history of exposure to any known teratogen.

Prenatal sonography showed a large omphalocele, which contained liver, stomach and possibly some bowel. In addition, dilation of the right renal pelvis and ureter were seen; the bladder was not visualized in several ultrasound scans. A small lesion appeared in the lumbosacral region measuring 0.9 x 0.7 cm, which was assumed to represent a small meningocele or closed spina bifida. The cranial structures were normal. Fetal echocardiogram revealed no cardiac defect. Prenatal chromosomal analysis obtained by amniocentesis showed a normal male karyotype (46, XY) and no evidence of structural chromosomal anomalies at the level of banding resolution of 450.

The child was born by caesarean section because of premature labor and cervical dilatation. Birthweight was 2130 g (P 30), height 44 cm (P 20), and head circumference 31.5 cm (P 30). Apgar scores were 6, 7, and 9, and the umbilical artery pH was 7.29. Immediately after birth, the baby was prophylactically intubated and assisted ventilation was started to prevent bowel distension due to ingested air.

On examination, we saw an appropriate for gestational age baby presenting with a large omphalocele with herniation of small bowel and liver covered by a thin, transparent membrane consisting of amnion (Fig. 1). Exstrophy of the meconium stained cloaca was seen medially at the caudal base of the omphalocele including bilateral exstrophy of the everted, bulging urinary bladder inferior to the umbilicus (Fig. 2 A, B). There was a single umbilical artery, anal atresia, a small split phallus and two pigmented folds below the rudimental penis with palpable masses suggestive of testicles on both sides (Fig. 2 A, B). The remainder of the physical exam and laboratory investigations were unremarkable.

Chest and abdominal X-ray revealed hemivertebrae in the lower thoracic and lumbar spine and a dysplastic os sacrum (Fig. 3). Additionally, fusion of 10th and 11th rib on the left side and absence of the 12th rib could be demonstrated. On the first day of life, cerebral ultrasound and echocardiography were, except for a PDA, normal.

Large omphalocele in a premature boy with OEIS complex

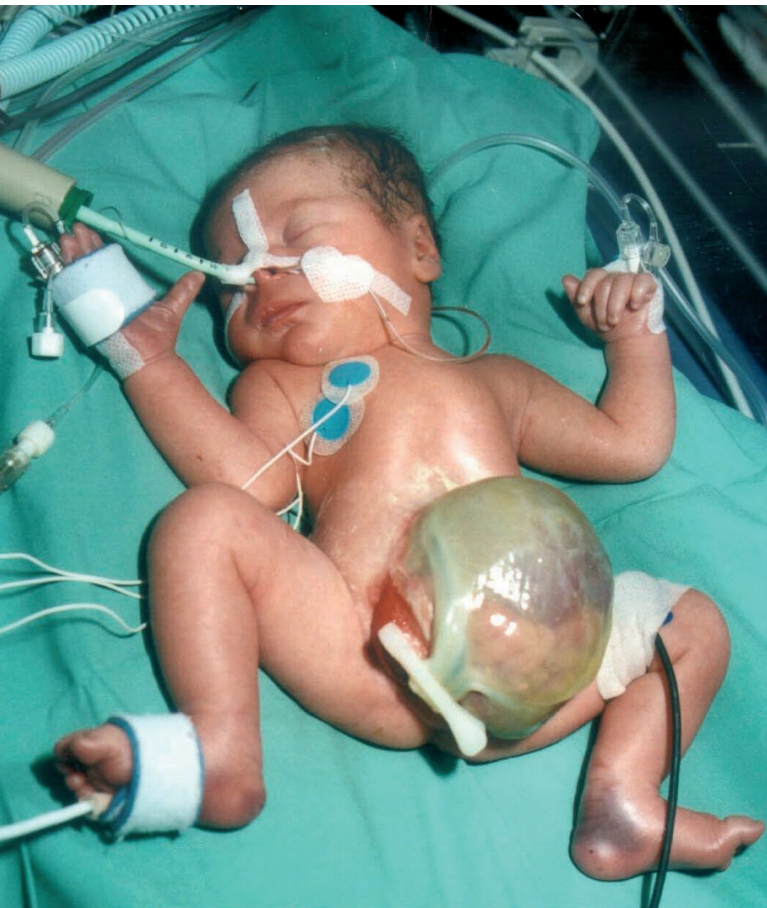

Fig. 1

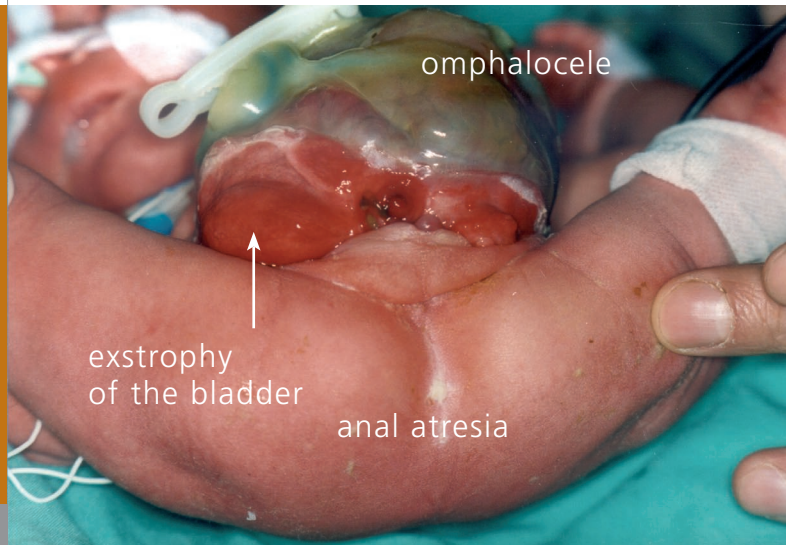


Fig. 2A

Omphalocele, anal atresia and exstrophy of the bladder

Meconium stained cloaca at the caudal base of the omphalocele, small split phallus and pigmented scrotum

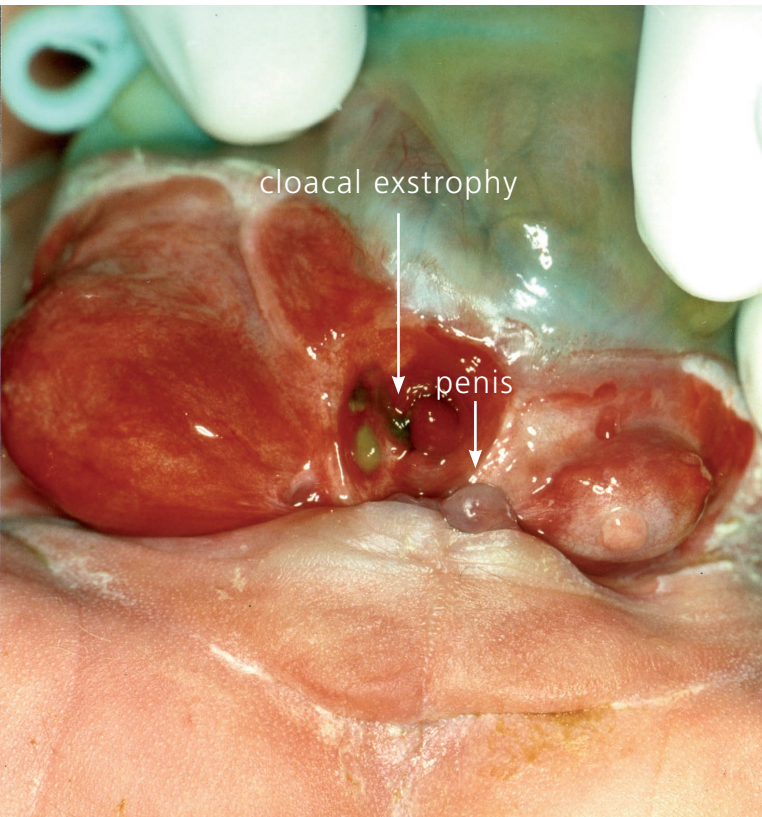


Fig. 2B

Ultrasound of the kidneys revealed dilated ureter and renal pelvis on the right and normal findings on the left side. No uterus or ovaries were seen. Ultrasound of the lumbar spinal cord revealed a tethered cord, a cystic abnormality next to the tethered cord resembling a meningocele, lipomyelocystocele or cystic lipoma and a dysplastic os sacrum.

Since the parents are US military personnel, the patient was transferred to the United States on day two of life. Regrettably, no further information on the patient's care and hospital course became available.

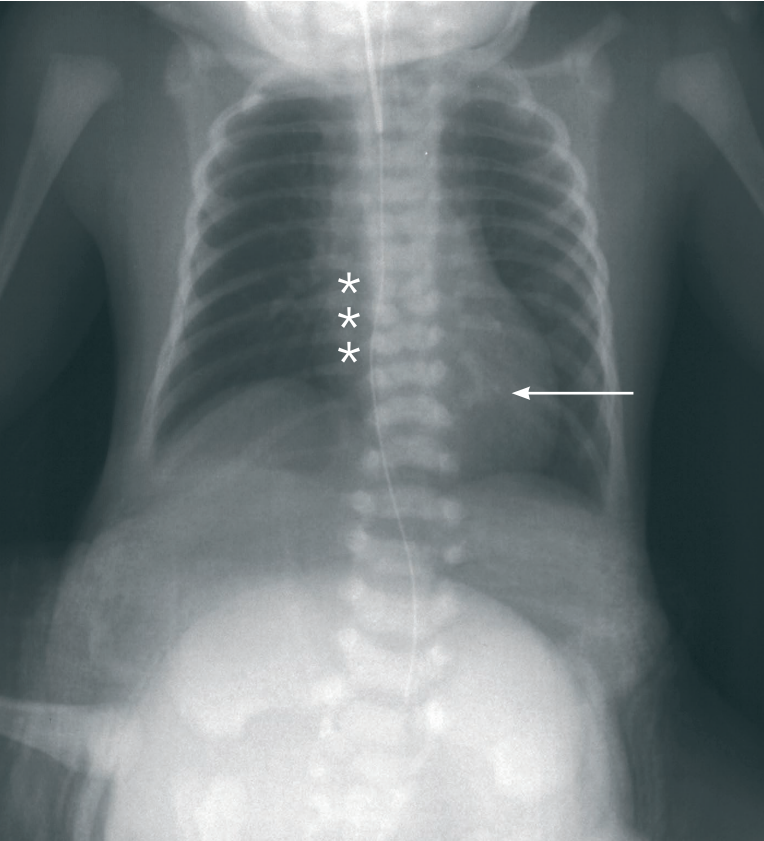


Fig. 3

Babygram: Spinal (asterisks) and rib malformations (arrow)

DISCUSSION

In 1978 Carey et al. (1) described an association of four severe congenital abnormalities of body wall development and proposed the term "OEIS complex" (omphalocele-exstrophy-imperforate anus-spinal defects). OEIS complex is a multiple development defect of different intestinal organs including the body wall. The incidence is very low with one in 200'000 to 400'000 pregnancies being affected (1). Only few living newborns fulfilling all defining criteria of OEIS complex have been reported.

The cloaca is an endoderm-lined cavity at the terminal portion of the hindgut that is in contact with the surface ectoderm at the cloacal membrane. The cloaca is divided into dorsal and ventral parts by a wedge of mesenchyma – the urorectal septum – which develops in the angle between the allantois and hindgut by the seventh week of embryogenesis. It represents a temporary embryonic structure where the genital, urinary and digestive system join caudally. Its correct development gives origin to the lower abdominal wall, bladder, intestine, anus, genitals and also part of the pelvic bones and lumbosacral spine.

Cloacal exstrophy (EC) presents with exstrophy of the bladder (EB), a wide-open cecal plate, a protruding limb of prolapsed distal ileum and an omphalocele of varying size. The prevalence of exstrophy of the bladder and cloacal exstrophy for living newborns has been estimated to be 1/35'597 and 1/200'233 respectively (2).

Recent publications merged the debate, whether EB and EC are two distinct disorders or part of a continuum, representing different levels of severity within the same spectrum of severe multiple congenital malformations (3-7).

Exstrophy of the bladder (EB) occurs chiefly in males (2). It is caused by incomplete median closure of the inferior part of the anterior abdominal wall. The anomaly is the result of failure of mesenchymal cells to migrate between the ectoderm of the abdomen and cloaca during the fourth week of gestation. As a result the abdominal muscles are absent or deficient. The ureteric orifices are exposed and urine dribbles intermittently from the everted bladder. Epispadia and wide separation of the pubic bones are associated with complete exstrophy of the bladder. In some cases the penis is divided into two parts, and the halves of the scrotum are widely separated.

Anorectal anomalies occur in about 1:2'500 live births and are more common in males. They manifest with various grades of anal stenosis/agenesis, imperforate anus or rectal agenesis/atresia. Additional anomalies are common in 6 out of 10 infants with anorectal atresia and stenosis (9). Most anorectal anomalies result from abnormal development of the urorectal septum resulting in incomplete separation of the cloaca into urogenital and anorectal portions.

The intestines are formed from the posterior part of the foregut, midgut and hindgut. The developing intestines herniate into the body stalk (the umbilical cord after further development) at the sixth or seventh week of embryogenesis. By the tenth week of gestation, the herniated intestinal loops begin to return through the intestinal ring back to the abdominal cavity. Omphalocele represents the failure of return of the intestinal loops into the body cavity. The incidence is approximately 1 in 3'500 births, but half of the infants with this condition are stillborn. In many cases of omphalocele, hypoplasia of the abdominal wall itself or deficiencies of abdominal musculature are evident.

Although development and migration of the above mentioned organs is impaired in OEIS complex, epithelial proliferation, morphogenesis, cellular differentiation, biochemical and functional maturation seem to be unaffected. Occasional reports have described the occurrence of OEIS complex in association with cardiac defects (10), severe limb defects (8) or craniofacial anomalies (11). In two cases, prenatal exposure to diazepam (12) and diphenylhydantoin (1) have been described as possible teratogens. In a report on 18 pairs of twins (13 monozygotic, 1 dizygotic, 4 of unknown zygosity), three out of thirteen monozygotic twins had concordant and five discordant malformations, respectively (7). The higher incidence of OEIS com-

plex in monozygotic twins than in dizygotic twins suggests a genetic contribution to the occurrence of this malformation, although the event of twinning and the occurrence of early malformation such as cloacal exstrophy might be causally related (13). The majority of published descriptions are based on clinically identified cases which seem to fulfill the criteria of OEIS complex which is a consistent and recognizable pattern of midline abdominal and pelvic defects that is distinct from other intestinal and genitourinary malformations (1, 6, 7, 14). The etiology of this malformation complex remains unclear. As proposed by Keppler-Noreuil (6), a genetic contribution to the occurrence of OEIS complex might be due to developmental control genes (homeobox genes) which provide positional values that determine a region's subsequent development. The alteration of the pattern of their expression causes morphological changes.

For a related case see COTM 02/2006: Exstrophy of the cloaca sequence

This article is dedicated to our teachers Otwin Linderkamp - emeritus Professor for neonatology - and Gholamali Tariverdian - emeritus Professor for human genetics and dysmorphology - at the University of Heidelberg in Germany

ACKNOWLEDGEMENT

REFERENCES

1. Carey JC, Greenbaum B, Hall BD. The OEIS complex (omphalocele, exstrophy, imperforate anus, spinal defects). *Birth Defects Orig Artic Ser* 1978;14:253-263
2. Martinez-Frias ML, Bermejo E, Rodriguez-Pinilla E, Frias JL. Exstrophy of the cloaca and exstrophy of the bladder: two different expressions of a primary developmental field defect. *Am J Med Genet* 2001;99:261-269
3. Bohring A. OEIS complex, VATER, and the ongoing difficulties in terminology and delineation. *Am J Med Genet* 2002; 107:72-76
4. Carey JC. Exstrophy of the bladder and the OEIS complex: one and the same. *Am J Med Genet* 2001;99:270
5. Kallen K, Castilla EE, Robert E, Mastroiacovo P, Kallen B. OEIS complex--a population study. *Am J Med Genet* 2000;92:62-68
6. Keppler-Noreuil KM. OEIS complex (omphalocele-exstrophy imperforate anus-spinal defects): a review of 14 cases. *Am J Med Genet* 2001;99:271-279
7. Lee DH, Cottrell JR, Sanders RC, Meyers CM, Wulfsberg EA, Sun CC. OEIS complex (omphalocele-exstrophy-imperforate anus-spinal defects) in monozygotic twins. *Am J Med Genet* 1999;84:29-33
8. Chen CP, Shih SL, Liu FF, Jan SW, Jeng CJ, Lan CC. Perinatal features of omphalocele-exstrophy-imperforate anus-spinal defects (OEIS complex) associated with large meningomyeloceles and severe limb defects. *Am J Perinatol* 1997;14:275-279
9. Cuschieri A. Descriptive epidemiology of isolated anal anomalies: a survey of 4.6 million births in Europe. *Am J Med Genet* 2001;103:207-215
10. Kant SG, Bartelings MM, Kibbelaar RE, Van Haeringen A. Severe cardiac defect in a patient with the OEIS complex. *Clin Dysmorphol* 1997;6:371-374

11. Haldar A, Sharma AK, Phadke SR, Jain A, Agarwal SS. OEIS complex with craniofacial anomalies--defect of blastogenesis? *Am J Med Genet* 1994;53:21-23
12. Lizcano-Gil LA, Garcia-Cruz D, Sanchez-Corona J. Omphalocele-exstrophy-imperforate-anus-spina bifida (OEIS) complex in a male prenatally exposed to diazepam. *Arch Med Res* 1995;26:95-96
13. Schinzel AA, Smith DW, Miller JR. Monozygotic twinning and structural defects. *J Pediatr* 1979;95:921-930
14. Smith NM, Chambers HM, Furness ME, Haan EA. The OEIS complex (omphalocele-exstrophy-imperforate anus-spinal defects): recurrence in sibs. *J Med Genet* 1992;29:730-732

SUPPORTED BY



CONTACT

Swiss Society of Neonatology

www.neonet.ch

webmaster@neonet.ch