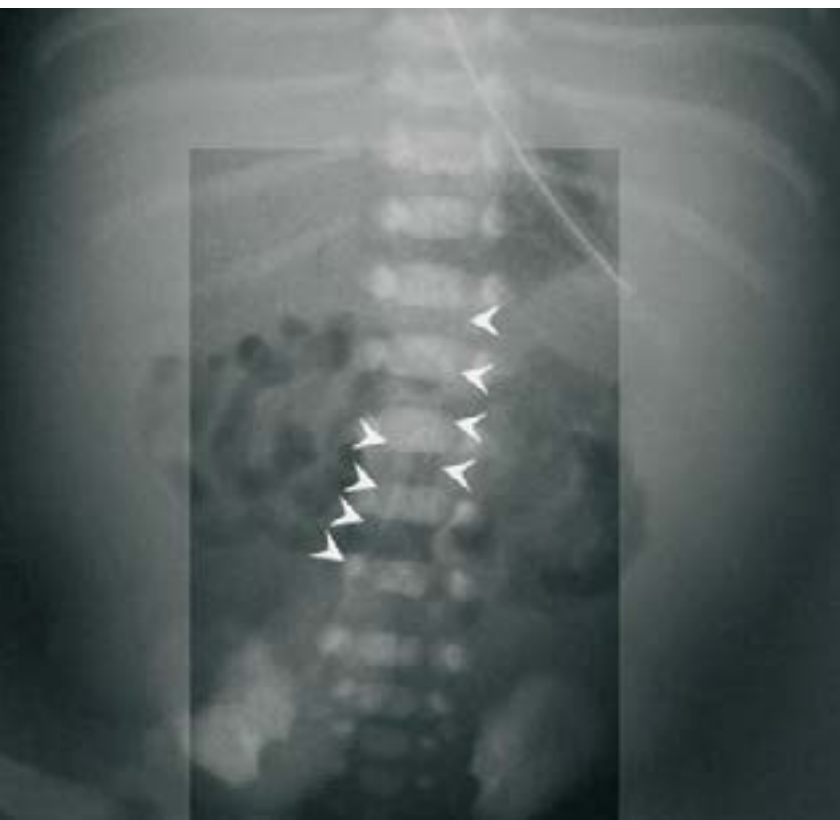

Idiopathic infantile
arterial calcification with
leukomalacia

October 2007



Khan JM, Asbeh JA, Department of Neonatology,
Al-Rahba Hospital, United Arab Emirates

A 2038 g male baby was born prematurely at 32 weeks' gestation by spontaneous vaginal delivery. Fetal ultrasound had shown possible absent corpus callosum, mildly dilated cerebral ventricles, polyhydramnios, subcutaneous edema, and fetal ascites. At delivery, the baby required tracheal intubation and positive pressure ventilation due to poor respiratory effort. Physical examination was remarkable for diffuse edema of the skin and subcutaneous tissue, hepatosplenomegaly (liver 3 cm below the right costal margin, spleen 4 cm below the left costal margin), ascites and bilateral scrotal edema. Initial laboratory results showed a hemoglobin of 154 g/L and a hematocrit of 0.47, a WBC of 14.7 G/l, thrombocytopenia of 70 G/l, normal electrolytes, a total protein of 45 g/L with an albumin of 18 g/L.

A babygram revealed cardiomegaly, probable ascites and faint calcifications delineating the abdominal aorta and common iliac vessels (Fig. 1). Abdominal ultrasound revealed hepatosplenomegaly, ascites, increased renal echogenicity, and diffuse arterial calcifications involving the aorta, common iliac, splenic, and left renal arteries, as well as peritoneal calcifications involving the visceral peritoneum overlying the liver and intestines. This was confirmed by abdominal computerized tomography (Fig. 2). An echocardiogram revealed a structurally normal heart, normal ventricular function, mild concentric left ventricular hypertrophy and multiple intracardiac as well as vascular calcifications.

Brain ultrasound on the 4th day of life showed dilated lateral ventricles, a poorly developed corpus callosum, and leukomalacia. The first week of life was complicated by disseminated intravascular coagulation, direct hyperbilirubinemia, and multifocal clonic convulsions. He was successfully extubated on the 9th day of life. Oxygen supplementation was discontinued on the 16th day of life. A brain CT scan obtained before discharge revealed extensive areas of leukomalacia, an underdeveloped corpus callosum, and multiple vascular calcifications mainly in the basal brain arteries (Fig. 3).

He was discharged at 37 days of age. The patient was readmitted twice for failure to thrive at 3 and 6 months of age and finally died at home one week later after having been discharged against medical advice.

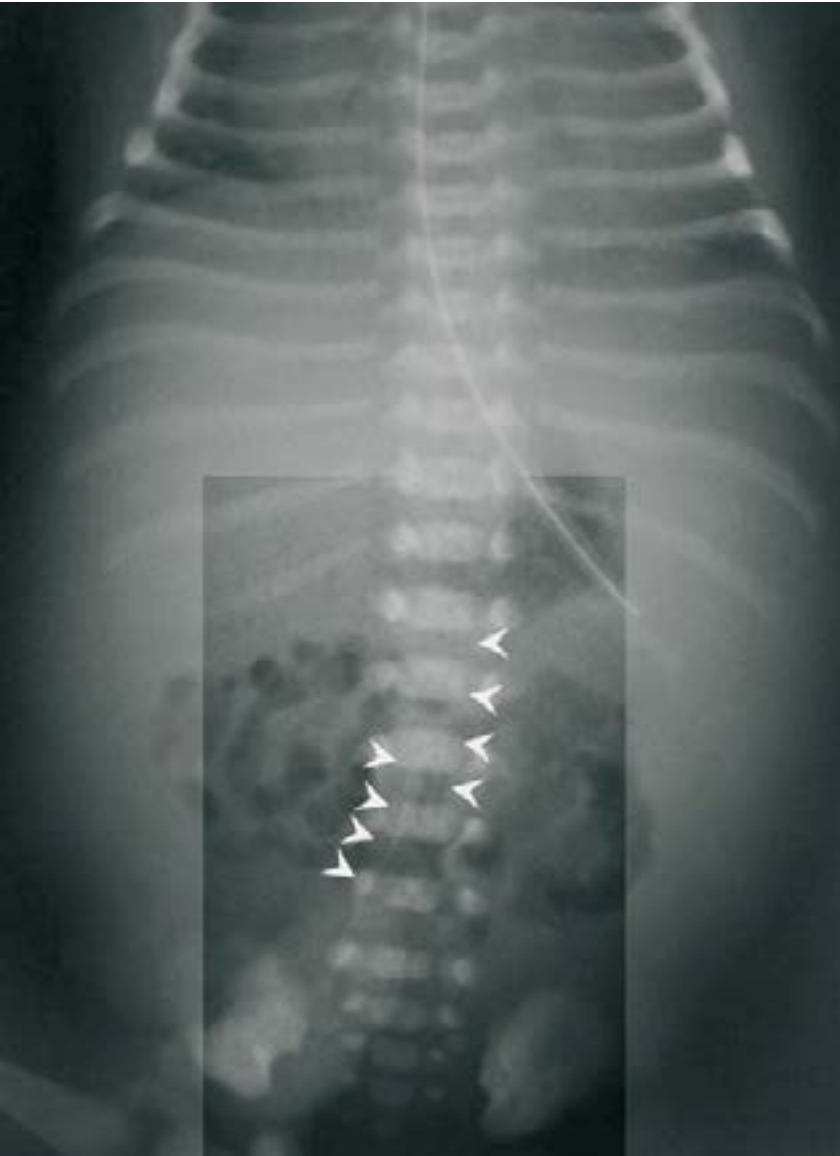

Fig. 1

Babygram showing cardiomegaly and aortic and iliac calcifications (arrow heads).

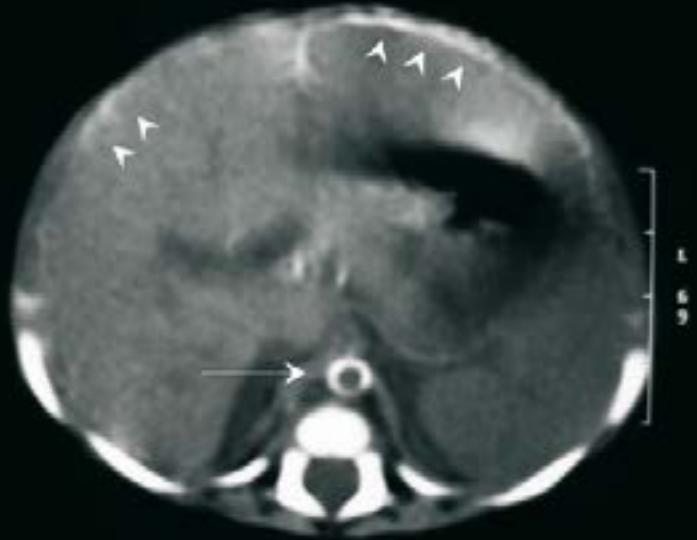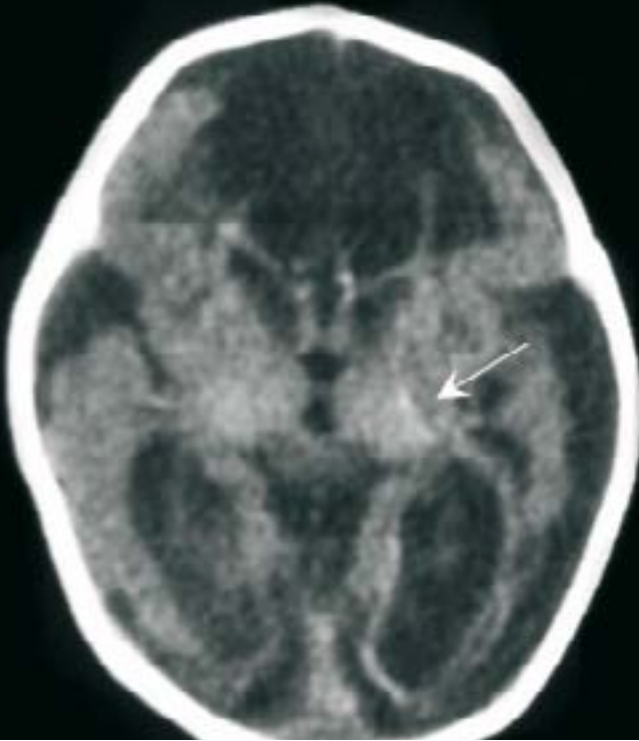


Fig. 2

Abdominal CT scan showing aortic calcifications (arrow) and calcification of the liver surface (arrow heads).

DISCUSSION

Idiopathic infantile arterial calcification is a diffuse disease of elastic and muscular arteries characterized by destruction and fragmentation of the arterial internal elastic membrane, deposition of calcium along the internal elastic membrane and intimal proliferation. It is a rare disorder. The first case was described by Bryant and White in 1901 (1). The number of reported cases in the literature exceeds 160 (2), but the true number of cases is probably much higher. Males and females are equally affected. There is considerable

**Fig. 3**

Brain CT scan showing extensive leukomalacia and some calcifications (arrow).

debate concerning the site of the primary histological defect. Some argue that calcification of the internal elastic membrane is the primary lesion, and intimal proliferation is secondary (3, 4); others feel that intimal proliferation is the primary lesion, with elastic degeneration and calcification occurring as secondary phenomena (5, 6). In either case, intimal proliferation usually leads to occlusion of the artery. The coronary arteries are most commonly involved.

The etiology is unknown, but there are several theories that have been presented in the literature: A) a hereditary disorder of connective tissue, supported by findings of calcium deposits in other elastic tissues such as ligaments (7); B) injury to or a defect of the endothelium may initiate the intimal proliferation (8); C) an alteration in iron metabolism that triggers calcium deposition (9); D) hemodynamic disturbances secondary to an insult or stress sustained in utero may prime the arteries for later development of idiopathic infantile arterial calcification.

The incidence of the disease in siblings lead to the theory of a genetic transmission (4, 5, 7, 9). The equal distribution of the disease between male and female contradicts a sex-linked chromosomal disorder. Whether this is a dominant or recessive trait is still under debate (5, 7), but an autosomal recessive transmission is thought to be most likely. Most recently, Rutch et al. were able to detect loss-of-function mutations in ecto-nucleotide pyrophosphatase/phosphodiesterase 1 (ENPP1) which was found in eight of eleven unrelated individuals with clinically established idiopathic infantile arterial calcification (10). This cell surface enzyme generates inorganic pyrophosphate, a solute that regulates cell differentiation and serves as an essential physiologic inhibitor of calcification.

Although the disease is often only diagnosed at autopsy, antenatal diagnosis has been reported (11).

It has been postulated that presentation in utero represents a more severe form of idiopathic infantile arterial calcification, associated with a higher incidence of aortic calcification. Fetal heart failure may result in polyhydramnios, fetal hydrops, and/or hypertension. In our case polyhydramnios and hydrops fetalis were diagnosed antenatally, and aortic calcification was recognized at birth.

Idiopathic infantile arterial calcification should be added to the list of differential diagnoses for non-immune fetal hydrops. Obtaining a detailed history from the parents, specifically whether they had a child die in infancy, could add valuable information. There is no evidence that early detection has any impact on the poor outcome of this disease process. Patients described in the literature died at ages ranging from stillbirth (11-14) to 28 months, with an estimated 85% of cases dying in the first 6 months of life (7, 9, 15). The usual cause of death is myocardial infarction from coronary artery occlusion. There have been rare reports of prolonged long-term survival. Some have also reported spontaneous regression of calcifications (16). Treatments with thyroid extract, estrogens, steroids, and diphosphonates have had some success (5, 7, 15), but the long-term effectiveness is still unclear.

It is important to consider the diagnosis of idiopathic infantile calcification in all cases of non-immune

CONCLUSION

hydrops fetalis. Aortic calcification can be visible on plain X-rays at birth. Ultrasound can be helpful in antenatal as well as postnatal diagnosis. CT scan easily demonstrates calcifications in the larger and smaller arteries.

REFERENCES

1. Bryant JH, White WH. A case of calcification of the arteries and obliterative endarteritis associated with hydronephrosis in a child aged 6 months. *Guy's Hosp Rep* 1901;55:17-28
2. Azancot A, Diehl R, Dorgeret S, et al. Isolated pericardial effusion in the human fetus: A report of three cases. *Prenat Diagn* 2003;23:193-197
3. Stanley RJ, Edwards WD, Rommel DA, et al. Idiopathic arterial calcification of infancy with unusual clinical presentations in sisters. *Am J Cardiovasc Pathol* 1988;2:241-245
4. Morton R. Idiopathic arterial calcification in infancy. *Histopathology* 1978;2:423-432
5. Vade A, Eckner FAO, Rosenthal IM. Computerized tomography in occlusive infantile arteriopathy. *Pediatr Cardiol* 1989;10:221-224
6. Witzleben CL. Idiopathic infantile arterial calcification - a misnomer? *Am J Cardiol* 1970;26:305-309
7. Meradji M, De Villeneuve VH, Huber J, et al. Idiopathic infantile arterial calcification in siblings: radiologic diagnosis and successful treatment. *J Pediatr* 1978;92:401-405
8. Chen H, Fowler M, Yu CW. Generalized arterial calcification of infancy in twins. *Birth Defects: Original Article Series* 1982;18:67-80

9. Anderson KA, Burbach JA, Fenton LJ, et al. Idiopathic arterial calcification of infancy in newborn siblings with unusual light and electron microscope manifestations. *Arch Pathol Lab Med* 1985;109:838-842
10. Rutsch F, Vaingankar S; Johnson K et al. Mutations in ENPP1 are associated with idiopathic infantile arterial calcification. *Nature Genet* 2003;34:379-381
11. Levine JC, Campbell J, Nadel A. Prenatal diagnosis of idiopathic infantile arterial calcification. *Circulation* 2001;103:325-326
12. Nagar AM, Hanchate V, Tandon A, Thakkar H, Chaubal NG. Antenatal detection of idiopathic arterial calcification with hydrops fetalis. *J Ultrasound Med* 2003;22:653-659
13. Carles D, Serville F, Dubecq J, Albert EM, Horovitz J, Weichhold W. Idiopathic arterial calcification in a still born complicated by pleural hemorrhage and hydrops fetalis. *Arch Pathol Lab Med* 1992;116:293-295
14. Liu CT, Singer DB, Frates R. Idiopathic arterial calcification in infancy. *Arch Pathol Lab Med* 1980;104:589-591
15. Moran JJ. Idiopathic arterial calcification of infancy. A clinicopathologic study. *Pathol Annu* 1975;10:393-417
16. Rosenbaum DM, Blumhagen JD. Sonographic recognition of idiopathic arterial calcification of infancy. *AJR* 1986; 146:249-250
17. Sholler GF, Yu JS, Bale PM et al. Generalized arterial calcification of infancy. Three case reports, including spontaneous regression with long-term survival. *J Pediatr* 1984;105:257-260

SUPPORTED BY



CONTACT

Swiss Society of Neonatology

www.neonet.ch

webmaster@neonet.ch