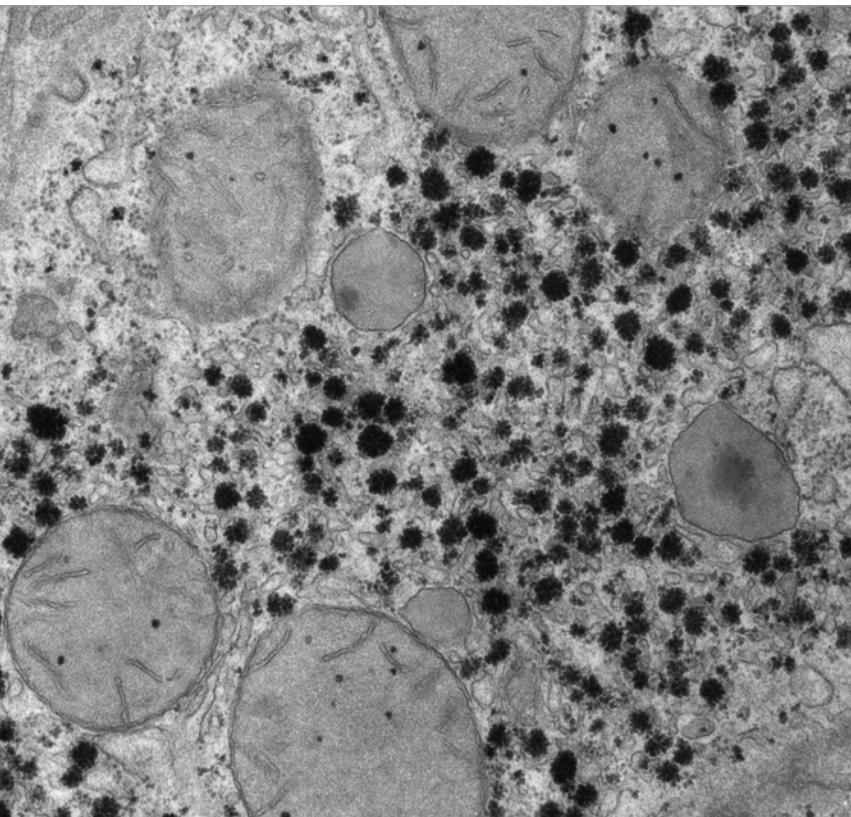


Unusual course of hyaline  
membrane disease –  
pulmonary interstitial  
glycogenosis

November 2016



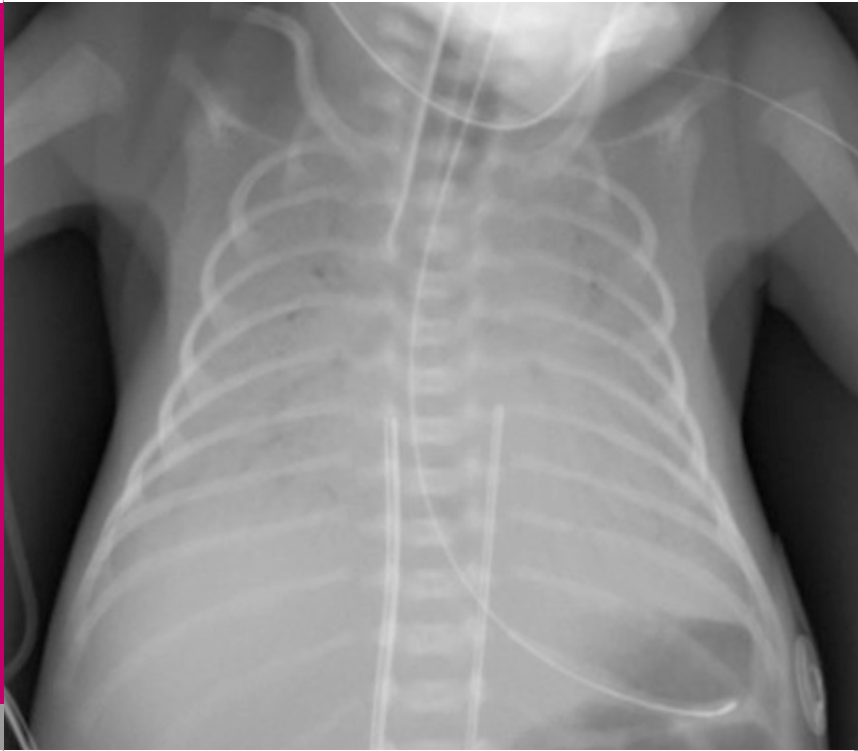Berger TM, Eng P, Regamey N, Hürlimann S, Neonatal and Pediatric Intensive Care Unit (BTM), Pediatric Pulmonology (EP, RN), Children's Hospital of Lucerne, Department of Pathology (HS), Cantonal Hospital of Lucerne, Switzerland

Title figure:

TEM of glycogen deposits in rat liver

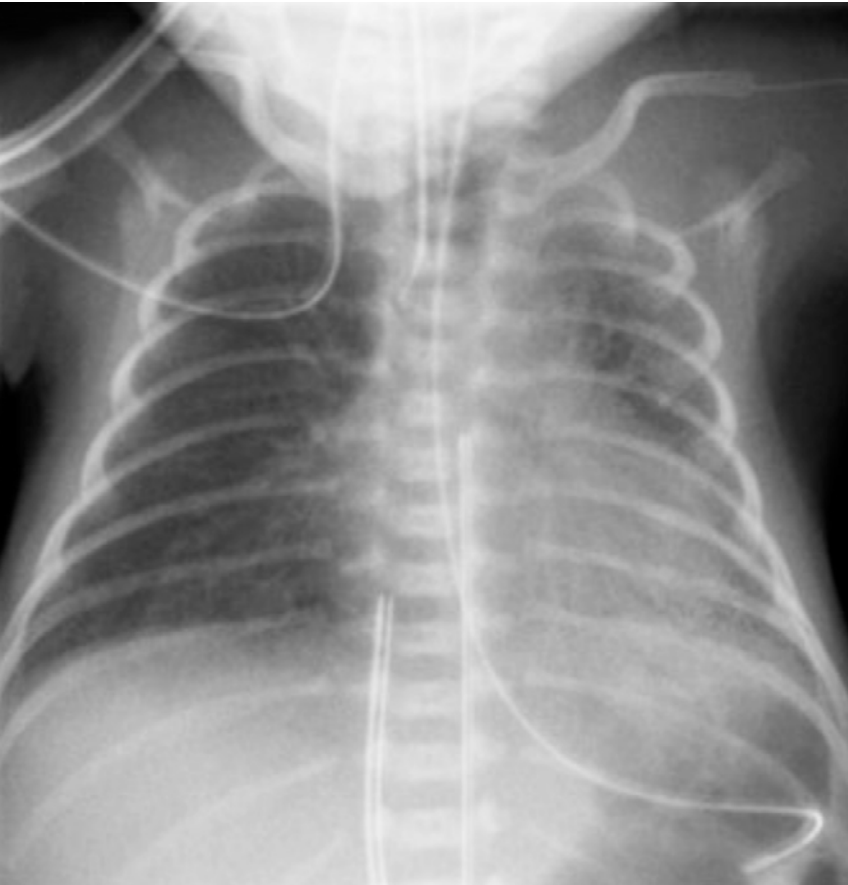(Source: [www.cellimagelibrary.org](http://www.cellimagelibrary.org))

The most common etiology of severe respiratory distress in very low gestational neonates is surfactant deficiency. Antenatal corticosteroids to enhance lung maturation, exogenous surfactant replacement therapy and various lung-protective modes of invasive and non-invasive respiratory support have revolutionized the prognosis for such infants. In contrast to infants born in the 1980s, the majority of these infants now survive without severe forms of bronchopulmonary dysplasia (BPD). In this report, we describe a VLGAN with unusually severe lung disease requiring prolonged respiratory support. The course did not correspond to typical hyaline membrane disease (HMD) and/or evolving BPD and the ultimate diagnosis could only be established by open lung biopsy.



**Fig. 1**

*Chest X-ray DOL 1 (age 2 hours: SIMV with  $FiO_2$  0.6, PIP 24 cmH<sub>2</sub>O, PEEP 5 cmH<sub>2</sub>O, rate 60/min): despite the fact that surfactant had been administered in the delivery room, there is bilateral white-out consistent with grade IV hyaline membrane disease.*

**Fig. 2**

*Chest X-ray DOL 1 (age 8 hours: HFOV with  $FiO_2$  0.34, MAP 11  $cmH_2O$ , amplitude 21, frequency 10 Hz): significantly improved aeration (right > left).*

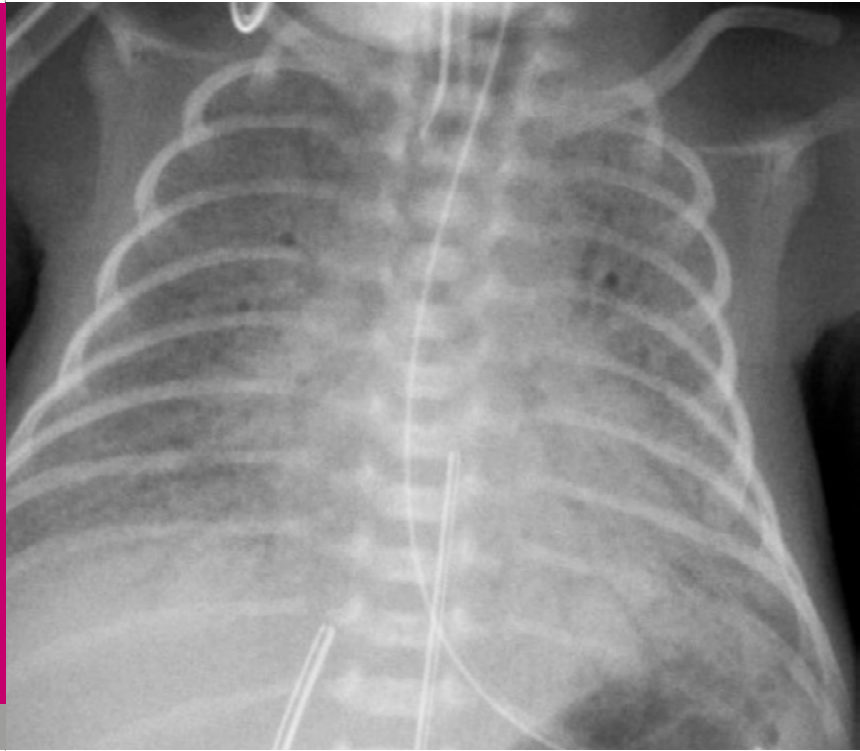
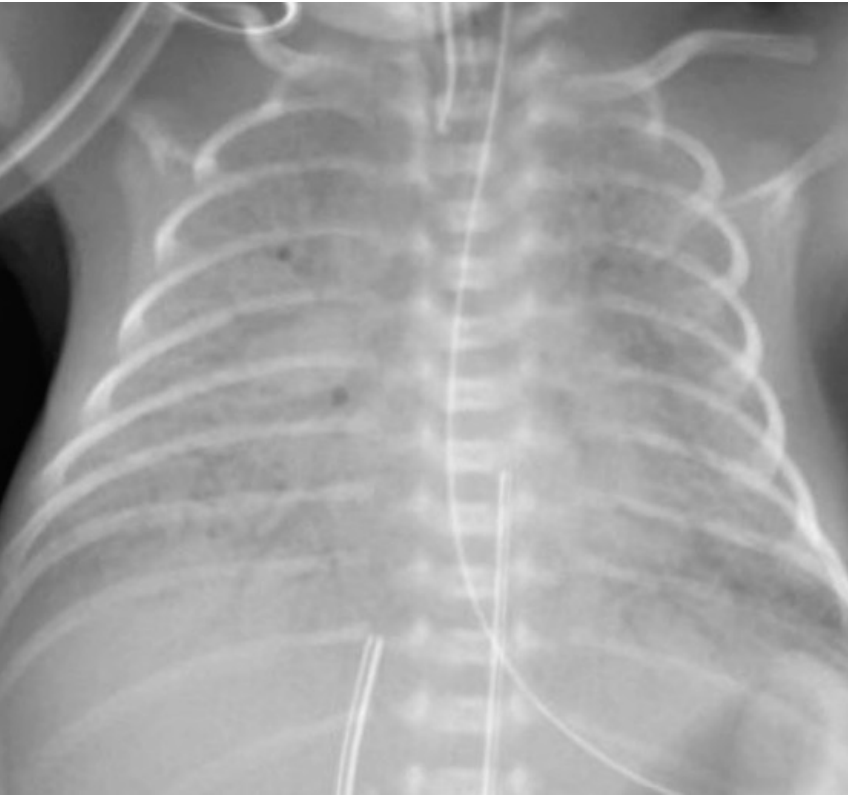
Fig. 3

*Chest X-ray DOL 4 (HFOV with  $FiO_2$  0.50, MAP 12  $cmH_2O$ , amplitude 26, frequency 10 Hz): worsening aeration with ground glass appearance and air bronchograms after pulmonary hemorrhage and a second dose of surfactant.*

**Fig. 4**

*Chest X-ray DOL 5 (HFOV with  $FiO_2$  0.80, MAP 14  $cmH_2O$ , amplitude 29, frequency 8 Hz): worsening aeration despite higher ventilator settings and a third dose of surfactant.*

## CASE REPORT

The mother, a 34-year-old G3/P1, was hospitalized at 28 4/7 weeks of gestation due to preeclampsia. A full course of antenatal corticosteroids was administered. The male infant was born to a by emergency Cesarean section at 29 0/7 weeks of gestation due to worsening preeclampsia and a retroplacental hematoma. The infant adapted well with Apgar scores of 5, 7 and 9 at 1, 5 and 10 minutes, respectively. Arterial and venous umbilical cord pH values were 7.28 and 7.35. The infant was stabilized on nCPAP and transferred to the neonatal intensive care unit. Due to worsening respiratory distress, the infant was intubated and surfactant was administered. The initial chest X-ray on conventional mechanical ventilation (SIMV) was consistent with grade IV hyaline membrane disease (Fig. 1); lung aeration improved once the infant was switched to high frequency oscillatory ventilation (HFOV) (Fig. 2).

On day of life (DOL) 4, the respiratory situation deteriorated again due to acute hemorrhagic pulmonary edema (Fig. 3). A second dose of surfactant was administered and a hemodynamic significant PDA was closed with ibuprofen. Twenty-four hours later, the patient was still requiring high ventilatory settings (Fig. 4); therefore, a third dose of surfactant was administered and, on DOL 7, a rescue attempt with hydrocortisone was undertaken. Ten days later, the patient's condition had improved remarkably and the boy could be switched from HFOV to SIMV (Fig. 5).

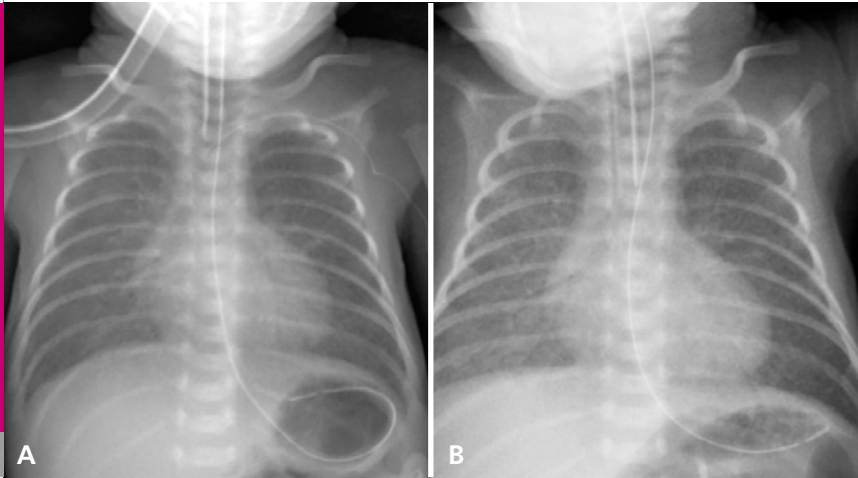


Because the course was felt to be extraordinary despite the infant's immaturity, genetic disorders of surfactant synthesis were sought. However, genetic analyses revealed no evidence of SP-B, SB-C or ABCA-3 deficiencies. In addition, no mutation was detected in the NKX2-1 gene which could cause brain lung thyroid syndrome.

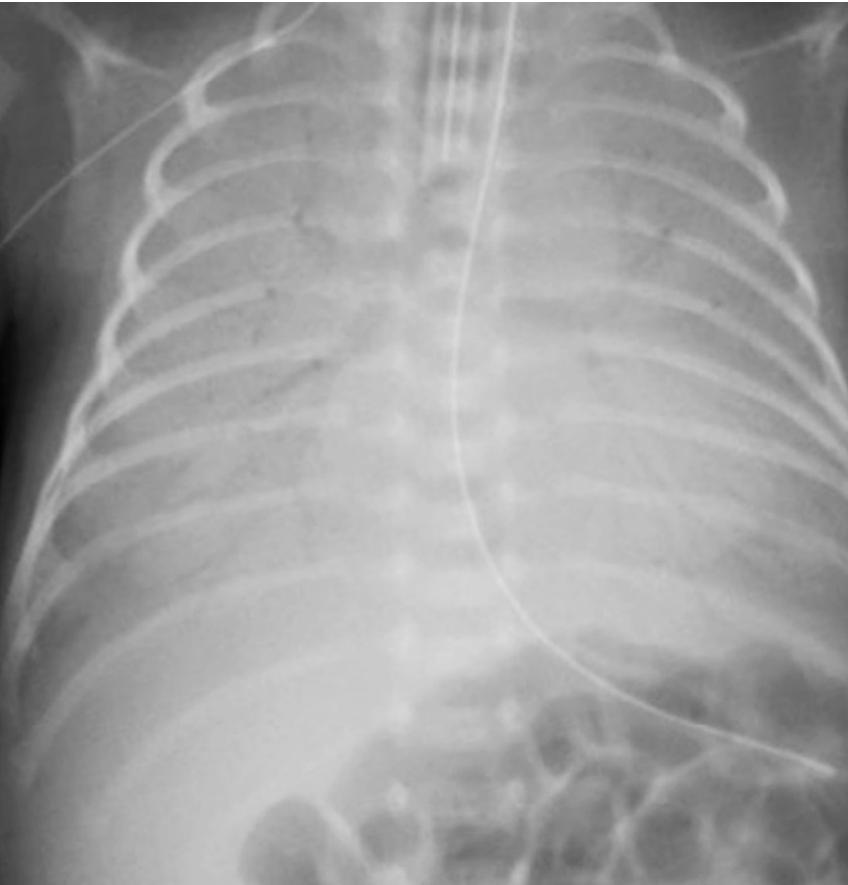
Coinciding with weaning of the corticosteroids and growth of *Enterobacter cloacae* in the tracheal aspirates on DOL 26, there was again near-total white out on chest X-ray (Fig. 6). The patient was stabilized with HFOV (Fig. 7) and hydrocortisone dosing was again increased.

On DOL 35, a CT scan of the chest was obtained to determine the extent and pattern of the lung abnormalities and to plan an open lung biopsy. The results of this imaging study were non-specific and showed dense infiltrates dorsally and bilateral, diffuse ground glass appearance of the lung parenchyma with thickened septae (Fig. 8).

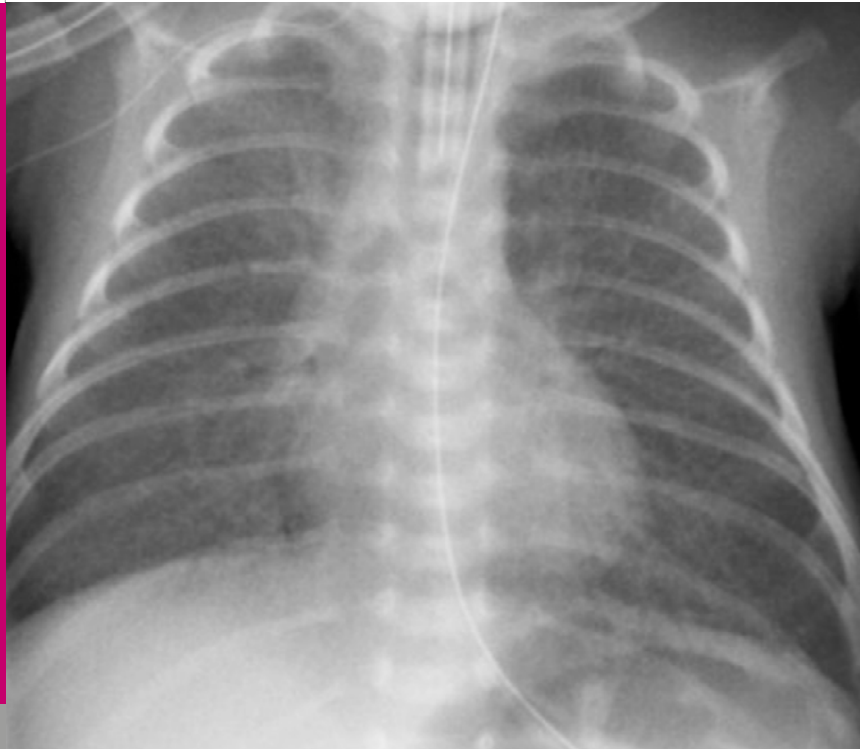On DOL 38 (i.e., at a corrected gestational age of 34 3/7 weeks), an open lung biopsy was performed. Histology was characterized by partially immature lung tissue with early alveolarization and dystelectatic areas, particularly in the biopsy from the lower lobe. The main finding, however, was marked alveolar septal widening by PAS-positive interstitial cells, consistent

**Fig. 5**

*Chest X-ray DOL 17 (HFOV with  $FiO_2$  0.21, MAP 9  $cmH_2O$ , amplitude 10, frequency 10 Hz): low ventilator setting following reintubation 24 hours earlier because of obstructive apnea (A: HFOV with  $FiO_2$  0.21, MAP 9  $cmH_2O$ , amplitude 10, frequency 10 Hz; B: SIMV with  $FiO_2$  0.25, PIP 18  $cmH_2O$ , PEEP 5  $cmH_2O$ , rate 50/min).*

**Fig. 6**

*Chest X-ray DOL 26 (SIMV with  $FiO_2$  0.65, PIP 19  $cmH_2O$ , PEEP 5  $cmH_2O$ , rate 50/min): near total whiteout and detection of *Enterobacter cloacae* in the tracheal aspirate.*



**Fig. 7**

*Chest X-ray DOL 26 (HFOV with  $FiO_2$  0.30, MAP 8  $cmH_2O$ , amplitude 22, frequency 8 Hz): rapid improvement following the administration of the 4<sup>th</sup> dose of surfactant.*

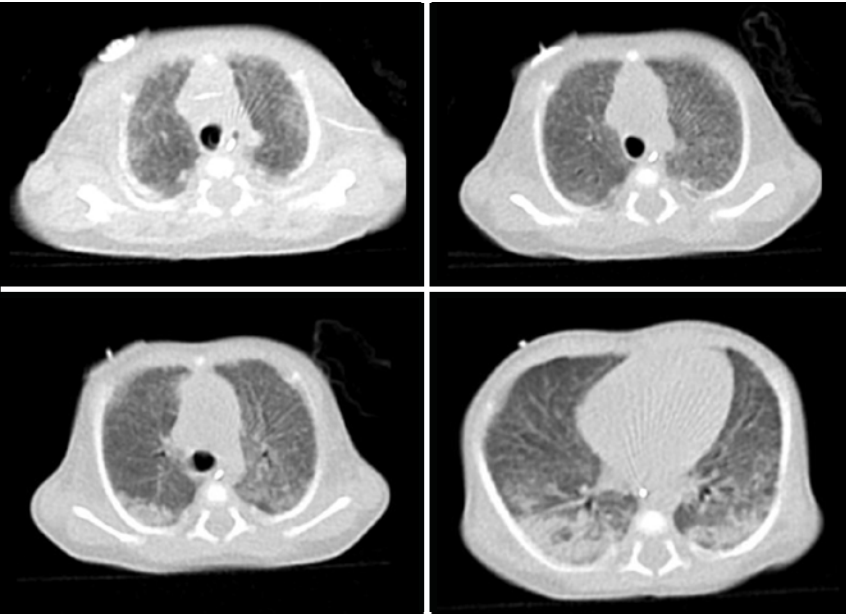
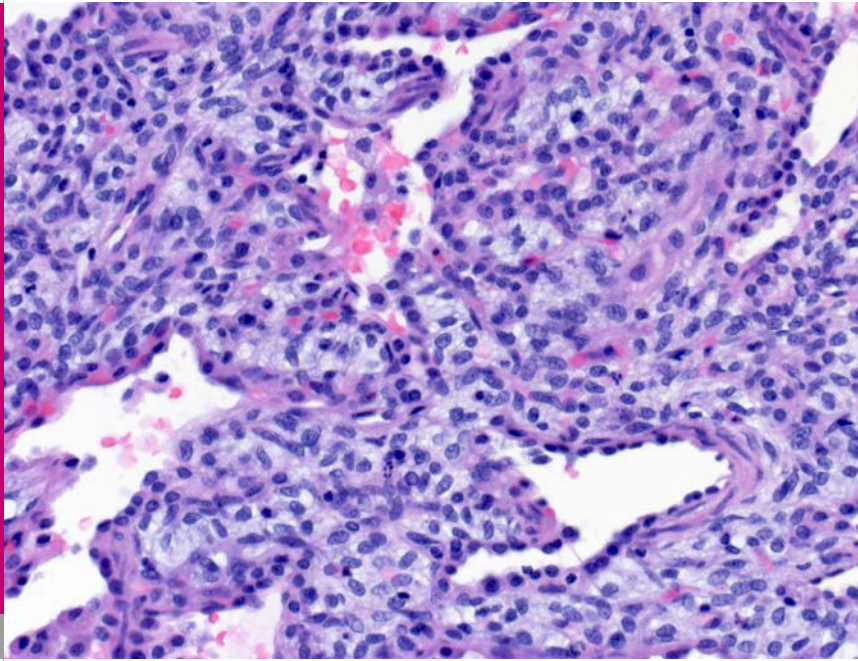


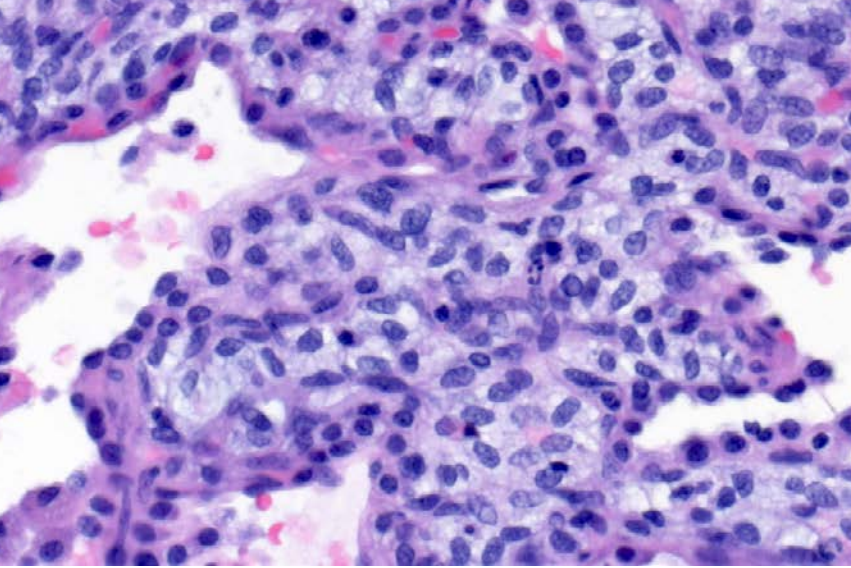
Fig. 8

*CT scan of the chest DOL 35: dense infiltrates dorsally, diffuse ground glass appearance of the lung parenchyma and thickened septae.*



**Fig. 9**

*Lung histology (HE stain, low power view): marked widening of pulmonary interstitial spaces.*

**Fig. 10**

*Lung histology (HE stain, high power view): the interstitium is expanded by round- to spindle-shaped cells with pale cytoplasm.*

with a diagnosis of pulmonary interstitial glycogenosis (PIG) (Fig. 9 – 12).

More than three weeks after the lung biopsy, the patient could finally be extubated to nCPAP on DOL 63. Treatment with hydroxychloroquine was begun three days later and hydrocortisone was successfully weaned. Finally, all respiratory support (including supplemental oxygen) could be discontinued on DOL 91. The patient was discharged home at a corrected age of 42 5/7 weeks while still on hydroxychloroquine. The patient's complex hospital course is summarized in Fig. 13.

On last follow-up at the age of three years, the boy had developed normally, was fully active and his physical examination was normal without any signs or symptoms of chronic lung disease. On chest X-ray there was no evidence of interstitial lung disease (Fig. 14).



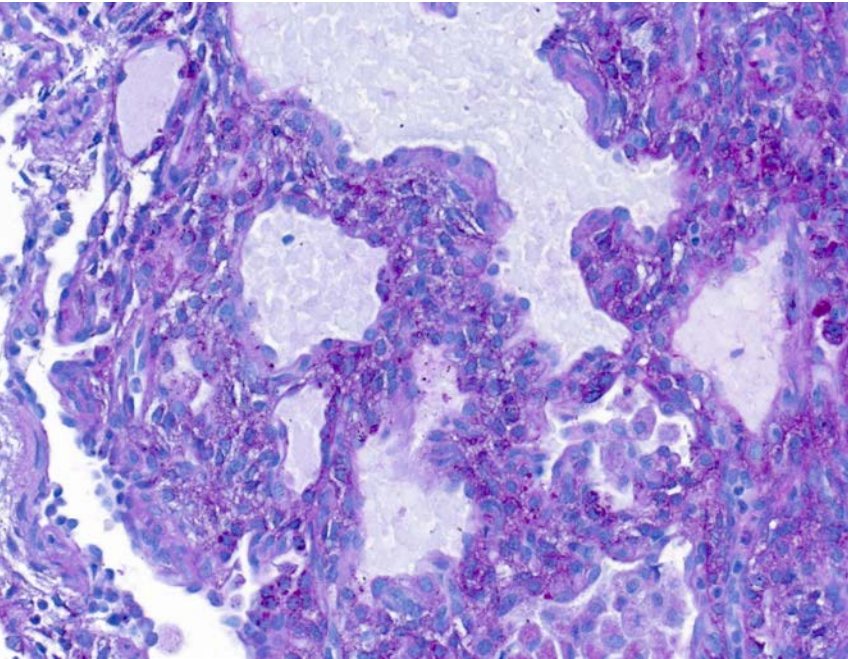


Fig. 11

*Lung histology (PAS stain): the cytoplasm of the interstitial cells contain masses of PAS-positive material, indicative of glycogen.*

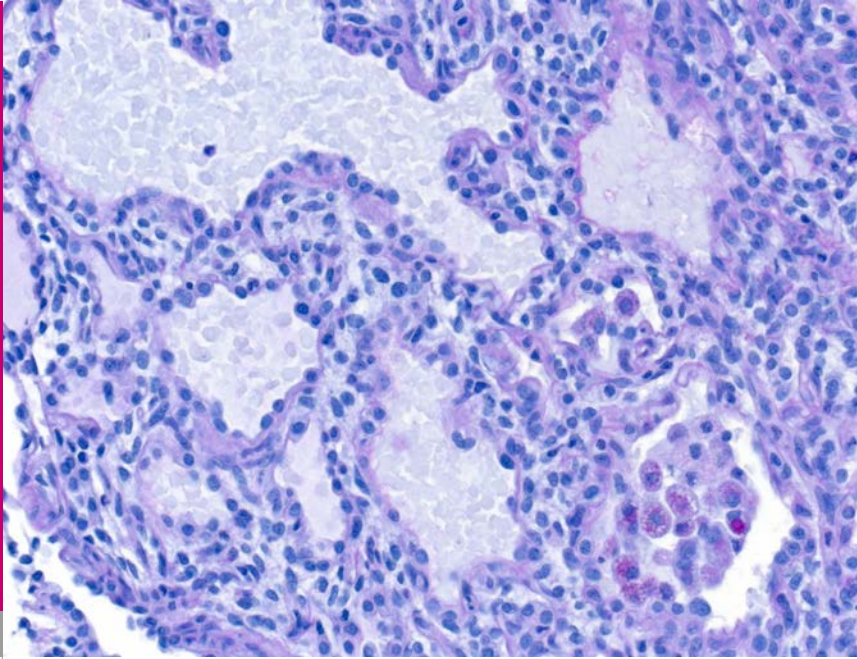


Fig. 12

*Lung histology (Diastase PAS stain): the PAS-positive cytoplasmic granules disappear after diastase treatment.*

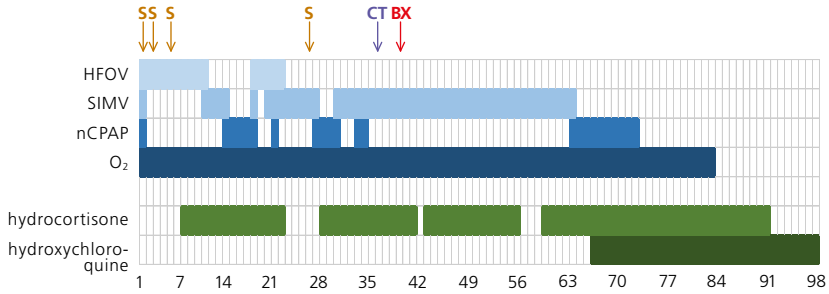


Fig. 13

*Hospital course: the patient required prolonged respiratory support, four doses of surfactant and multiple courses of corticosteroids which were eventually weaned after the introduction of hydroxychloroquine (S: surfactant, CT: computed tomography of the chest, BX: open lung biopsy).*

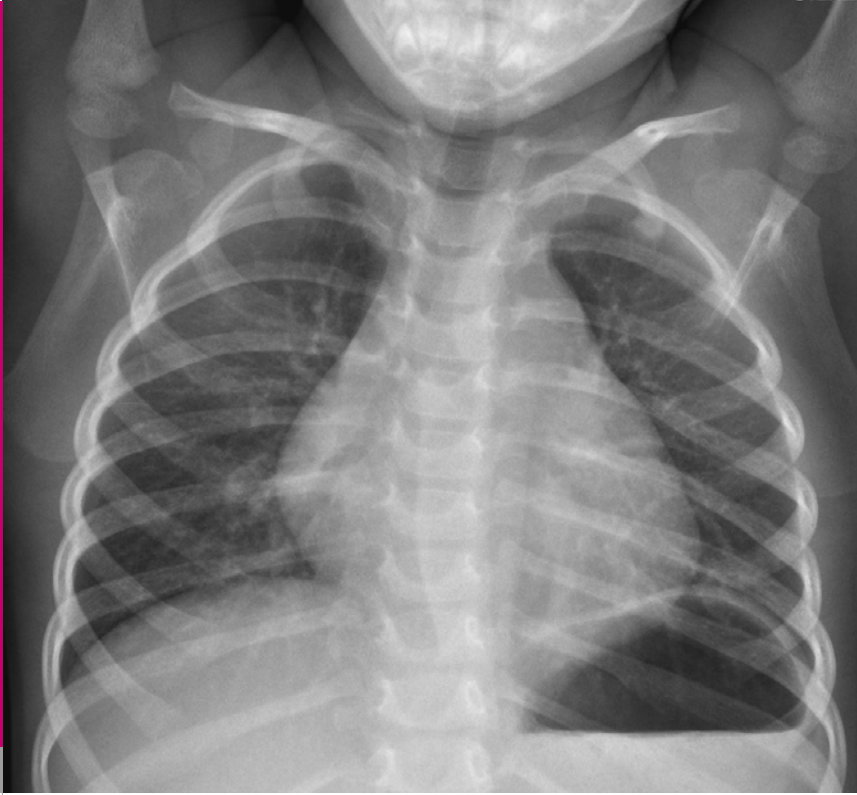

Fig. 14

*Chest X-ray at the age of three years: ne evidence of interstitial lung disease.*

Children's interstitial lung disease (chILD) has an estimated prevalence of 1.3 to 3.6/1'000'000 (1, 2). The term refers to a heterogeneous group of rare and diffuse lung diseases associated with significant morbidity and mortality (3). ChILD syndrome requires the presence of at least 3 of the following 4 criteria in the absence of other known disorders: a) respiratory symptoms (cough, rapid breathing, or exercise intolerance), b) respiratory signs (resting tachypnea, crackles, retractions, digital clubbing, failure to thrive, or respiratory failure), c) hypoxemia, and d) diffuse infiltrates on chest X-ray or computed tomography (CT) scan (4). The diagnostic approach to patients with suspected chILD syndrome is complex and based on history, physical examination, imaging studies, pulmonary function testing, genetic testing, bronchoalveolar lavage and, in most cases, an open lung biopsy. High-resolution CT is a useful tool for demonstrating the type of abnormality, the extension and distribution of the disease, and for identifying optimal biopsy sites avoiding sampling errors when biopsies are taken randomly (4).

Pulmonary interstitial glycogenosis (PIG) was first described in 2002 by Canakis et al. (5). They found similar histopathology findings in seven patients with atypical neonatal lung disease: expansion of the interstitium by spindle-shaped cells containing periodic-acid Schiff (PAS) positive diastase labile material consistent with glycogen. Electron microscopy revealed primitive

interstitial mesenchymal cells with few cytoplasmic organelles and abundant monoparticulate glycogen.

Canakis et al. speculated that PIG appeared to be caused by selective dysmaturity of interstitial cells without apparent effects on type 2 alveolar or endothelial cell differentiation (5). Of interest, glycogen accumulation does not occur in interstitial cells during normal lung development; in contrast, it does accumulate in primitive epithelium. Thus, it has been suggested that PIG represents an aberration in lung development rather than an inflammatory or reactive process (4).

Since its first description, a number of additional case reports of PIG have been published (6–19). In some of these patients, PIG was the only abnormal finding (i.e., idiopathic PIG), while others had additional pathologies (e.g., congenital heart disease, lung growth abnormalities, pulmonary hypertension). In an analysis of 187 patients by the chILD Research Co-operative from the US, six patients with idiopathic diffuse PIG were reported; in addition, 19 of 46 patients with lung growth abnormalities also displayed patchy PIG (20).

Many patients with PIG have been treated with corticosteroids and most of these have shown a clinical response. It has been speculated that the beneficial effect from corticosteroid therapy results from an acceleration of the maturation process rather than from modifying inflammation (5, 19).

Prognosis of patients with isolated PIG appears to be good (19); fatal cases have only been reported in a patient with extreme prematurity and BPD (5), a patient with severe lung growth abnormality (11), and patients with severe pulmonary hypertension (12, 19).

## REFERENCES

1. Dinwiddie R, Sharief N, Crawford O. Idiopathic interstitial pneumonitis in children: a national survey in the United Kingdom and Ireland. *Pediatr Pulmonol* 2002;34:23–29 ([\*Abstract\*](#))
2. Griese M, Haug M, Brasch F, et al. Incidence and classification of pediatric diffuse parenchymal lung diseases in Germany. *Orphanet J Rare Dis* 2009;4:26 ([\*Abstract\*](#))
3. Popler J, Lesnick B, Dishop MK, Deterding RR. New coding in the International Classification of Diseases, Ninth Revision, for children's interstitial lung disease. *Chest* 2012;143:774–780 ([\*Abstract\*](#))
4. Cazzato S, di Palma E, Ragazzo V, Ghione S. Interstitial lung disease in children. *Early Hum Dev* 2013;89:S39-S43 ([\*Abstract\*](#))
5. Canakis AM, Cutz E, Manson D, O'Brodoovich H. Pulmonary interstitial glycogenosis: a new variant of neonatal interstitial lung disease. *Am J Respir Crit Care Med* 2002;165:1557–1565 ([\*Abstract\*](#))
6. Onland W, Molenaar JJ, Leguit RJ, et al. Pulmonary interstitial glycogenosis in identical twins. *Pediatr Pulmonol* 2005;40:362–366 ([\*Abstract\*](#))
7. Deutsch GH, Young LR. Histologic resolution of pulmonary interstitial glycogenosis. *Pediatr Dev Pathol* 2009;12:475-480 ([\*Abstract\*](#))
8. Lanfranchi M, Allbery SM, Wheelock L, Perry D. Pulmonary interstitial glycogenosis. *Pediatr Radiol* 2010;40:361–365 ([\*Abstract\*](#))
9. Castillo M, Vade A, Lim-Dunham JE, Masuda E, Massarani-Wafai R. Pulmonary interstitial glycogenosis in the setting of lung growth abnormality: radiographic and pathologic correlation. *Pediatr Radiol* 2010;40:1562–1565 ([\*Abstract\*](#))



10. Smets K, Van Daele S. Neonatal pulmonary interstitial glycogenesis in a patient with Hunter syndrome. *Eur J Pediatr* 2011;170:1083–1084 (no abstract available)
11. King BA, Boyd JT, Kingma PS. Pulmonary maturational arrest and death in a patient with pulmonary interstitial glycogenesis. *Pediatr Pulmonol* 2011;46:1142–1145 (*Abstract*)
12. Alkhorayyef A, Ryerson L, Chan A, Phillipos E, Lacson A, Adatia I. Pulmonary interstitial glycogenesis associated with pulmonary hypertension and hypertrophic cardiomyopathy. *Pediatr Cardiol* 2013;34:462–466 (*Abstract*)
13. Radman MR, Goldhoff P, Jones KD, et al. Pulmonary interstitial glycogenesis: an unrecognized etiology of persistent pulmonary hypertension of the newborn in congenital heart disease? *Pediatr Cardiol* 2013;34:1254–1257 (*Abstract*)
14. Ehsan Z, Montgomery GS, Tiller C, Kisling J, Chang DV, Tepper RS. An infant with pulmonary interstitial glycogenesis: clinical improvement is associated with improvement in the pulmonary diffusion capacity. *Pediatr Pulmonol* 2014;49:E17–E20 (*Abstract*)
15. Ross MK, Ellis LS, Bird LM, Hagood JS. Pulmonary interstitial glycogenesis in a patient ultimately diagnosed with Noonan syndrome. *Pediatr Pulmonol* 2014;49:508–511 (*Abstract*)
16. Siomos AK, Mitchell MB, Fonseca BM. Successful surgical repair of a massive window duct in a 1-month old with aniridia and pulmonary interstitial glycogenesis. *Cardiol Young* 2015;25:594–596 (*Abstract*)
17. Sanchez-de-Toledo J, González-Peris S, Gran F, et al. Pulmonary interstitial glycogenesis: a reversible underlying condition associated with D-transposition of the great arteries and severe persistent pulmonary hypertension. *World J Pediatr Congenit Heart Surg* 2015;6:480–483 (*Abstract*)

18. Jiskoot-Ermers MEC, Antonius TAJ, Looijen-Salamon MG, Wijnen MHAW, Loza BF, van Heijst AFJ. Irreversible respiratory failure in a full-term infant with features of pulmonary interstitial glycogenosis as well as bronchopulmonary dysplasia. Am J Perinataol Rep 2015;5:e36 – e140 (Abstract)
19. Deutsch GH, Young LR. Lipofibroblast phenotype in pulmonary interstitial glycogenosis. Am J Respir Crit Care Med 2016;193:694 – 696 (no abstract available)
20. Deutsch GH, Young LR, Deterding RR, et al. Diffuse lung disease in young children – application of a novel classification scheme. Am J Respir Crit Care Med 2007;176:1120 – 1128 (Abstract)

SUPPORTED BY



CONTACT

Swiss Society of Neonatology

[www.neonet.ch](http://www.neonet.ch)

[webmaster@neonet.ch](mailto:webmaster@neonet.ch)