


SWISS SOCIETY OF NEONATOLOGY

Life and death of a butterfly
child born in a resource-
limited country

January 2017



Alfonso Deliz O, Berger TM, Gubler D, Rundu State Hospital (ADO, BTM), Rundu, Namibia, The Children's Hospital at Westmead (GD), New South Wales, Australia

Title figure:

Butterfly wing scales. Colored scanning electron micrograph (SEM) (Source: www.tagesanzeiger.ch)

Epidermolysis bullosa (EB) is a rare genetic connective tissue disorder that has an overall incidence of approximately 19 per one million live births (1). Epidermolysis bullosa affects gender, every racial and ethnic background equally. There are many genetic and symptomatic variations of EB, but all share the prominent feature of extremely fragile skin that blisters and tears following minor friction or trauma. Because of their delicate skin, children with EB are often termed «butterfly children,» in reference to the delicate wings of a butterfly. Epidermolysis bullosa is always painful, often pervasive and debilitating. Daily wound care, pain management, and protective bandaging are the only treatment options available for people with EB.

Several previous Cases of the Month have described patients with EB (see COTM 05/2003: Bart's syndrome with severe encephalopathy: a delayed diagnosis; COTM 08/2005: Epidermolysis bullosa; COTM 08/2010: Neonatal blistering – a butterfly child). These reports have discussed genetic aspects, clinical presentations, histopathological findings, as well as differential diagnoses. In contrast, the following report will focus on palliative aspects and the pain management of this disorder in a low-income country.

CASE REPORT

A male infant was born at Rundu State Hospital in the Kavango region of Namibia by normal vaginal delivery at term to a 29-year-old HIV-negative G3/P3/A0 (one twin pregnancy). Only one of the three previously born children was still alive; two of them had died (one in 2009 and one in 2014) presumably from complications of junctional epidermolysis bullosa (JEB), which was confirmed histologically in the infant born in 2014.

The current pregnancy was uncomplicated, and the Apgar scores were 9, 9 and 10 at 1, 5, and 10 minutes, respectively. There was asymmetric intrauterine growth restriction with a birth weight of 2500 g ($P < 5$), a birth length of 50 cm ($P < 50$) and a head circumference of 35.0 cm ($P < 50-75$). Immediately after birth, an extensive area of denuded skin was noted on the right lower leg (Fig. 1). Broad spectrum antibiotics (ampicillin and gentamicin) were started. Over the next few hours and days, new painful blistering lesions became apparent on the left elbow (Fig. 2), the right thigh, the left lower abdomen (Fig. 3) and the perianal region (Fig. 4).

Based on the family history and the clinical appearance, a diagnosis of JEB was made. The parents were again informed that JEB is a genetic disorder that is transmitted from the parents to the child, which explained the third occurrence in the family. Nevertheless, the father blamed the mother for the disease of her children.

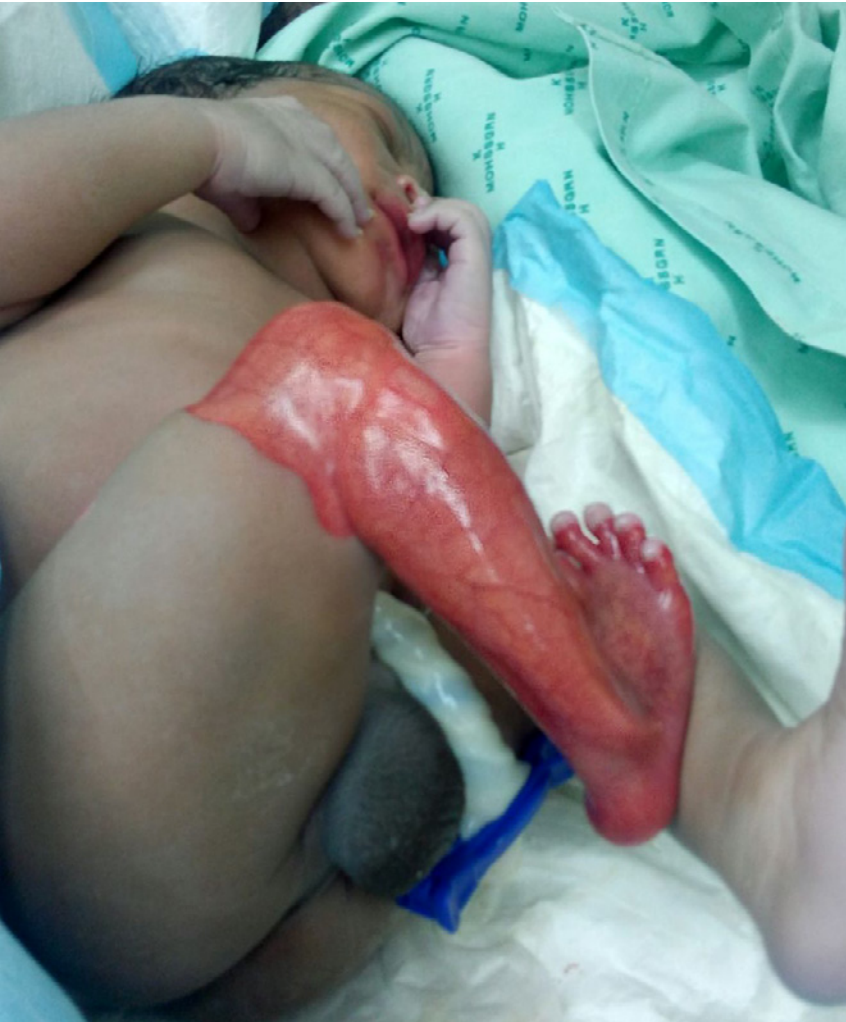

Fig. 1

Immediately after birth, an extensive area of denuded skin was noted on the right lower leg.

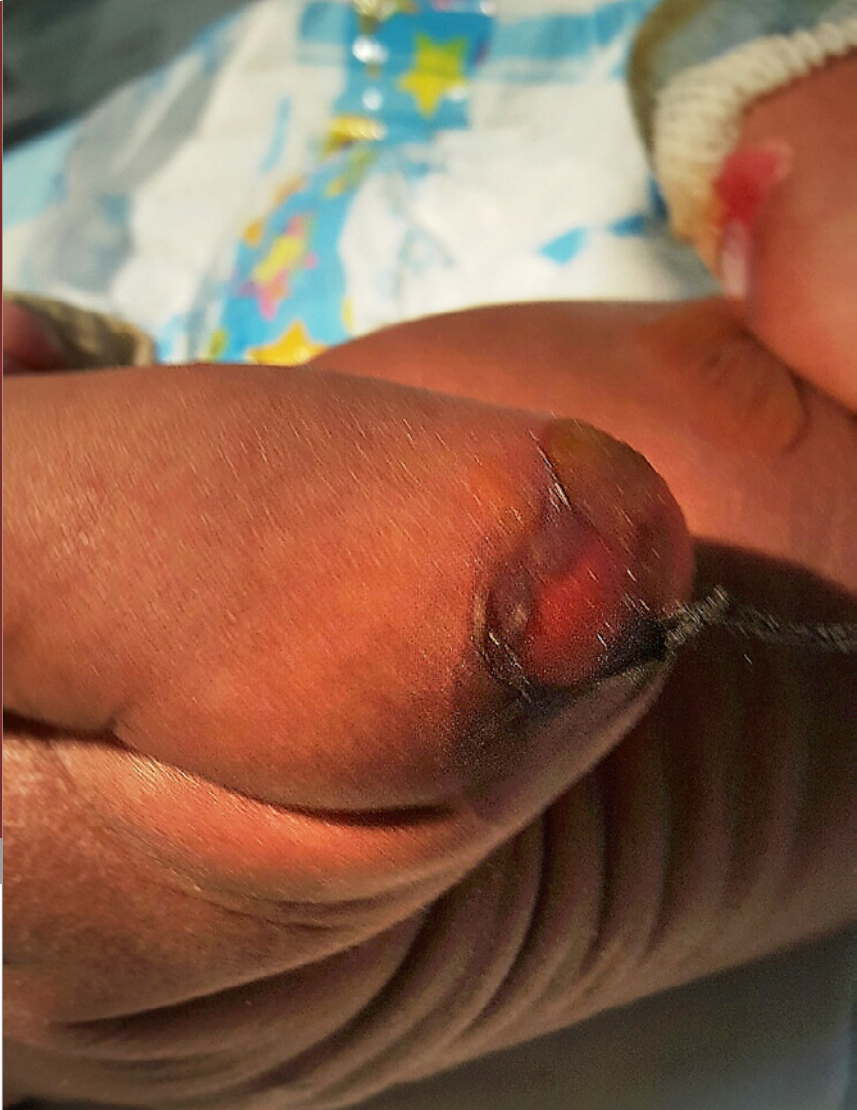

Fig. 2

Within hours after delivery, new blistering skin lesions appeared (right elbow).

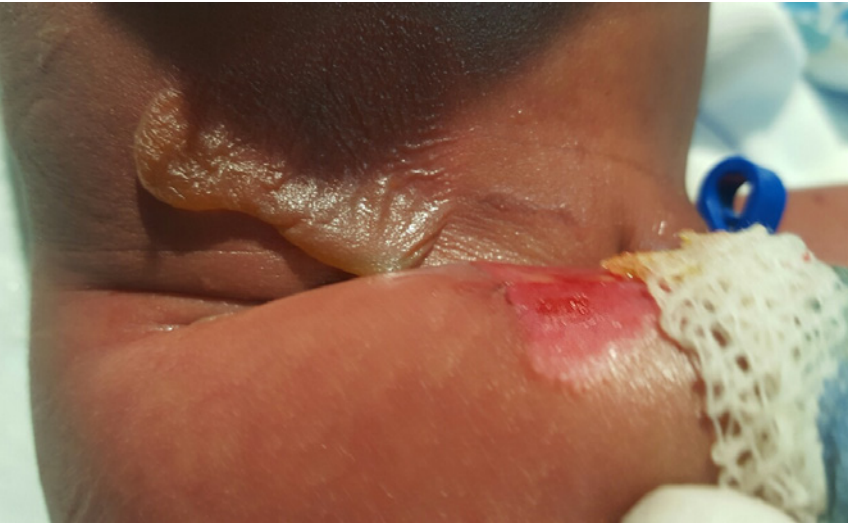

Fig. 3

A large blister over the left lower abdomen became visible within the first days of life.

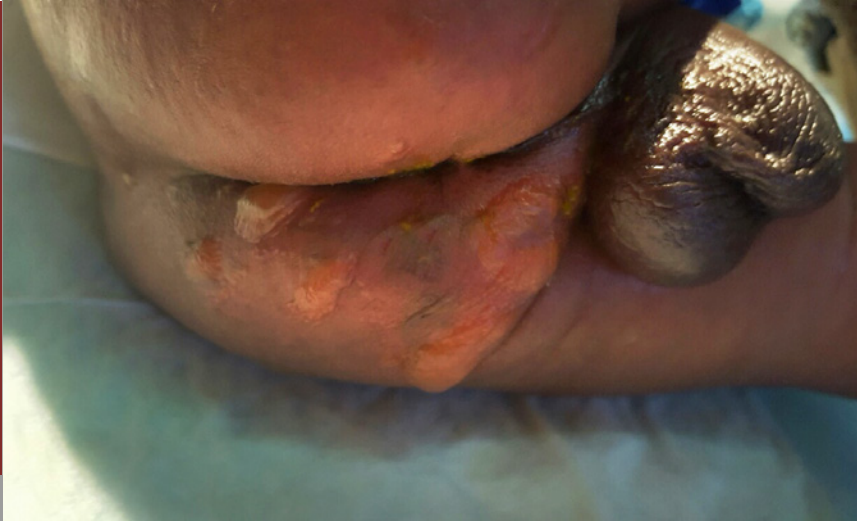

Fig. 4

Extensive perianal skin lesions appeared within the first days of life.

After discharge from the hospital, the mother brought her baby to the hospital twice per week for dressing changes and cleaning of the wounds. Acetaminophen was the only analgesic drug used in this patient; more potent drugs, including opioids were not available. Unfortunately, there was rapid progression of the skin lesions and the baby died from septic shock shortly after readmission to the hospital at one month of age.

DISCUSSION

There are three main types of EB: simplex (70% of all EB cases), dystrophic (25% of all EB cases) and junctional (5% of all EB cases). Junctional epidermolysis bullosa (JEB) is separated into two categories, namely the Herlitz type and the Non-Herlitz type (2). The Herlitz type of JEB is very severe, and individuals with this condition often do not survive infancy. The Non-Herlitz type includes several subtypes that cause mild to severe blistering of the skin present at birth or shortly thereafter (3, 4). JEB is inherited in an autosomal recessive pattern. It is caused by mutations in the LAMB3, COL17A1, or LAMC2, and LAMA3 genes (2). There is no cure for JEB. Treatment is focused on management of blistering and prevention of secondary infections (3). Based on our patient's family history, Herlitz type JEB was the likely diagnosis.

Meticulous wound care is extremely important, but, particularly in severe cases, daily bandaging takes hours and is very painful. Thus, provision of appropriate analgesia is a central issue. In a recent review, Goldschneider and colleagues published evidence-based care guidelines for the treatment of pain in EB patients (5). The recommendations include a section on pain care in infants with EB, which emphasizes that procedures are one of the major sources of pain for infants with EB and wound care specifically requires a multidisciplinary team approach to ensure consistent and optimized pain control. They mention that many

infants will require analgesics with bathing and dressing changes. In this context, NSAIDs, acetaminophen and opioids can be used, as for older patients. Codeine, however, is not recommended when alternatives are available, as some neonates lack the capacity to metabolize the drug into active metabolites, and clinical responses are highly variable at all ages, due to polymorphisms in codeine's metabolic pathway. Severely affected newborns with deep tissue damage may require extensive pharmacologic support to achieve a level of comfort. These infants may require around the clock or continuous infusion of opioids and an adjuvant. In addition, oral ketamine has been used to supplement opioids when pain associated with dressing changes is severe (5).

As described above, acetaminophen is the only analgesic drug available for infants at Rundu State Hospital in Namibia. A 2014 report of the Worldwide Palliative Care Alliance (WPCA) and the World Health Organization (WHO) called «Global Atlas of Palliative Care at the End of Life» emphasized that palliative care is a human rights issue (6). The vast majority of children (98%) in need of palliative care at the end of life belong to low and middle-income groups. The African Region has the majority of the world's children in need of palliative care (49%), followed by the Southeast Asian (24%) and Eastern Mediterranean regions (12%).

Access to essential medicines should be part of the minimum core content of the right to the highest attainable standard of health (6). Fourteen palliative care medications are currently on the WHO Essential Drug List, including acetylsalicylic acid, ibuprofen, acetaminophen, codeine, and morphine. Access to opioid medication for pain control is an enormous problem worldwide (Fig. 5). It has been estimated that 80% of the world's population lacks adequate access to opioid medications for pain control. Australia, Canada, New Zealand, the United States, and several European countries account for more than 90% of the global consumption of opioid analgesics (6).

For neonates and infants less than 3 months of age, the WHO (7) recommends acetaminophen 10 mg/kg/dose every 6–8 hours as the oral / rectal non-opioid analgesic; the guidelines warn that children who are malnourished or in a poor nutritional state are more likely to be susceptible to toxicity at standard dose regimens due to reduced natural detoxifying glutathione enzyme. In addition to acetaminophen, ibuprofen can be used in older infants (> 3 months) and children. Intravenous or subcutaneous morphine at a dose of 25–50 mcg/kg/dose every 6 hours is recommended as the first-line strong opioid for opioid-naïve neonates; for infants > 1 month of age, oral immediate release morphine (80–200 mcg/kg/dose every 4

Access to Morphine Around the World



Fig. 5

Access to morphine around the world: country size is adjusted to reflect opioid use per death from cancer or HIV/AIDS (source: Global Access to Pain Relief Initiative (GAPRI) 2008–2010).

CONCLUSION

The presented case serves to illustrate that palliative care is underdeveloped in most of the world, and outside North America, Europe, and Australia, access to quality palliative care is very rare. Barriers to palliative care development are lack of appropriate policies, lack of education and severely limited availability of essential palliative care medications (6). As Brennan has pointed out: «palliative care is an international human right» (8).

Acknowledgment

We would like to thank Prof. J.J. Collins (Pain and Palliative Care Service, The Children's Hospital at Westmead, Sydney, Australia) for his careful review of the manuscript.

1. Fine JD. Inherited epidermolysis bullosa. *Orphanet J Rare Dis* 2010;5:12 (*Abstract*)
2. Junctional epidermolysis bullosa. Dystrophic Epidermolysis Bullosa Research Association of America (<http://www.debra.org/junctional>, accessed October 22, 2016)
3. Junctional epidermolysis bullosa. Gene Reviews (initial posting: February 22, 2008; last update: January 2, 2014) (<http://www.ncbi.nlm.nih.gov/books/NBK1125>, accessed October 22, 2016)
4. Junctional epidermolysis bullosa. Genetics Home Reference (September 2009) (<http://ghr.nlm.nih.gov/condition/junctional-epidermolysis-bullosa>, accessed October 22, 2016)
5. Goldschneider KR, Good J, Harrop E, et al. Pain care for patients with epidermolysis bullosa: best care practice guidelines. *BMC Medicine* 2014;12:178 (*Abstract*)
6. WPCA and WHO. Global atlas of palliative care at the end of life (January 2014) (http://www.who.int/nmh/Global_Atlas_of_Palliative_Care.pdf, accessed October 23, 2016)
7. WHO Steering Group on Pain Treatment Guidelines. WHO guidelines on the pharmacological treatment of persisting pain in children with medical illnesses (2012) (http://apps.who.int/iris/bitstream/10665/44540/1/9789241548120_Guidelines.pdf, accessed October 24, 2016)
8. Brennen F. Palliative care as an international human right. *J Pain Symptom Manage* 2007;33:494–499 (*Abstract*)

SUPPORTED BY  **Vifor Pharma**

CONTACT Swiss Society of Neonatology
www.neonet.ch
webmaster@neonet.ch